



Laparoscopic nerve-sparing radical hysterectomy without uterine manipulator for cervical cancer stage IB: description of the technique, our experience and results after the era of LACC trial

Andreas Kavallaris¹ · Nektarios Chalvatzas¹ · Antonios Gkoutzioulis¹ · Dimitrios Zygouris¹

Received: 21 April 2020 / Accepted: 7 October 2020
© Springer-Verlag GmbH Germany, part of Springer Nature 2020

Abstract

Purpose The aim of this study is to evaluate surgical data and oncological outcome of laparoscopic nerve-sparing radical hysterectomy without uterine manipulator for cervical cancer stage IB, over the last 8 years.

Methods This retrospective study includes 32 patients with cervical cancer FIGO stage (2009) IB who underwent laparoscopic nerve-sparing radical hysterectomy without using any kind of uterine manipulator. Patients were eligible if they had squamous cell carcinoma, adenocarcinoma, or adeno-squamous carcinoma, and no para-aortic lymph node involvement by imaging or after frozen section. The median value and range were assessed for operative outcomes and relapse rate and disease-free survival rate were evaluated using the Kaplan–Meier method.

Results In the study, 32 patients were included and among them 27 women were stage IB1 (18 cases with tumor size 2–4 cm) and 5 women stage IB2 (FIGO stage 2009). The median age of patients was 50.5 years (range 31–68) and median body mass index (B.M.I) was 25.3 kg/m² (range 19–33.5 kg/m²). The average operating time was 228 min (range 147–310 min) and median hospital stay was 2.7 days (range 2–7 days). Approximate blood loss was 188 ml (range 120–300 ml). After a median follow-up of 37 months, we had 2 recurrences out of 32 cases and no death. Especially for patients with FIGO stage (2009) IB1, the recurrence rate was 3.7% (1/27). The 3-year PFS was 93.7% and the number at risk 23 (71.8%) and especially for the IB1 stage (2009) women, the 3-year PFS was 96.1% and the number at risk 21 (77.7%). The 3-year OS was 100% with no. at risk 71.8%.

Conclusions Laparoscopic nerve-sparing radical hysterectomy without uterine manipulator is feasible and safe surgical procedure for cervical cancer with acceptable surgical and oncological outcomes in the hands of well-trained and experienced laparoscopic surgeons. Our retrospective study reveals better oncological outcome compared to other studies on the minimally invasive approach, where uterine manipulator was routinely used and no vaginal sealing of the tumor was made.

Keywords Laparoscopic radical hysterectomy · Uterine manipulator · Cervical cancer · Nerve sparing · Minimally invasive surgery

Introduction

Cervical cancer is the most common cancer of the female genital tract in the developing world and the second most common gynecological malignancy, after endometrial cancer, in developed countries [1]. The classical surgical

management of early-stage cervical carcinoma is radical hysterectomy and bilateral pelvic lymphadenectomy.

This surgical approach was first described by Ernst Wertheim [2], modified by Okabayashi in 1921 [3] and re-popularized by Meigs [4] in the 1950s and by Piver in the 1970s [5]. It is well known that radical hysterectomy is associated with significant intraoperative and postoperative morbidity, and the last successful effort to reduce this morbidity was the establishment of laparoscopic approach [6] and later the nerve-sparing approach [7, 8].

This surgical technique of laparoscopic radical hysterectomy for cervical cancer associates a radical procedure complying, oncologic principles with a minimal invasive

✉ Dimitrios Zygouris
dzygouris@hotmail.com

¹ Department of Gynecologic Oncology, St Luke's Hospital, Thessaloniki, Greece

approach. Over the last 2 decades, laparoscopic radical hysterectomy is performed routinely around the world [7]. Moreover, nerve-sparing technique became a more frequent technique reducing postoperative pelvic organs' dysfunction and improving patients' quality of life [8].

Until 2018, most of the existed data showed the same oncological outcome for open and laparoscopic approach in radical hysterectomy [6, 7] with less peri- and postoperative morbidity for the laparoscopic technique [9, 10].

However, after publication of LACC trial (Laparoscopic approach to Cervical Cancer) [11], many concerns have been raised over the safety of minimally invasive approach in cervical cancer that were further increased after recent publication of retrospective data [12–16]. Among the other reported explanations of high recurrence rate in the minimally invasive arm of LACC trial, the use of uterine manipulator during the surgery was considered responsible for cell dissemination and the worst oncological outcome [17, 18].

In the present study, we present our data on laparoscopic nerve-sparing radical hysterectomy without uterine manipulator for cervical cancer stage IB, over the last 8 years. This is a technique that we have previously reported [19] and we report a single center's surgical and oncological outcomes pertaining laparoscopic approach of cervical cancer stage IB.

Patients and methods

This is a retrospective study to evaluate surgical outcomes, recurrence rates and overall survival in patients with cervical cancer stage IB that underwent laparoscopic nerve-sparing radical hysterectomy without uterine manipulator in department of gynecologic oncology in St. Luke's Hospital, Thessaloniki, Greece.

The hospital's ethical committee approved the study's protocol and we analyzed the records of patients diagnosed with cervical cancer between January 2011 and January 2018. In the study, patients with FIGO stage IB (2009) were included (squamous cell carcinoma, adenocarcinoma, or adeno-squamous carcinoma of the uterine cervix without any lymph node involvement by imaging studies or after frozen section). In all the cases, a type C1 radical hysterectomy (Querleu–Morrow classification) [20] was performed laparoscopically.

Exclusions criteria for the laparoscopic nerve-sparing radical hysterectomy were bulky uterus > 12 weeks size or cases that vaginal removal of the uterus was considered possible to require morcellation. Patients were excluded if final pathology report revealed any component of neuroendocrine carcinoma and we also excluded patients that had a history of abdominal/pelvic radiotherapy. Previous abdominal surgery was not a contraindication for the laparoscopic approach.

All the patients underwent laparoscopic nerve-sparing radical hysterectomy with pelvic lymphadenectomy and all the procedures were documented on record system (image and video documentation Endobase, Olympus). A computerized database was used for recording data on patient's age, body mass index, operating time, hospital stay, blood loss, major postoperative complications and morbidity.

Preoperatively all patients had undergone clinical staging, MRI for evaluation of lymph node status and tumor size, haemogram, liver and kidney blood tests. Patients were admitted the day of surgery and had only a bowel enema. All patients had an initial diagnosis of cervical cancer either by punch biopsy or conization. All the procedures were conducted at our institution by the same surgical team. None of the surgeries required conversion to laparotomy.

Intraoperatively, we administer a single shot of prophylactic antibiotic (cefuroxime 1.5 g and metronidazole 500 mg IV) and antithrombotic prophylaxis with low-molecular-weight heparin started 8 h after the operation.

We never used uterine manipulator in any case and we always worked with CO₂ pressure < 12 mmHG, in a Trendelenburg position.

Operation was abandoned in patients with positive para-aortic lymph nodes on frozen section and all specimens underwent photo- documentation with measurement of the parametrial and vaginal cuff length.

Surgical procedure

The surgical procedure of laparoscopic nerve-sparing radical hysterectomy is a standardized technique, as we have it previously described [19].

After performing pneumoperitoneum with Veress needle, we import five trocars: a 10-mm port through umbilicus for the camera, a 5-mm port suprapubic, two 5-mm ports lateral to the visualized inferior epigastric vessel and the last 5 mm in Palmer's point. As we use no uterine manipulator, the fifth port is used by the second assistant for uterine or bowel manipulation with an atraumatic forceps.

We continue the operation with complete inspection of the abdominal cavity (liver, gall bladder, stomach, peritoneum, omentum, small and large intestine), removal of small bowel out of the pelvis and inspection of the inner genital organs. Pelvic lymphadenectomy is performed bilaterally as we have previously reported [21] and then we identify inferior hypogastric and splanchnic nerves.

More specific we identify ureter at its crossing point with the common iliac artery and then we go medially towards sacral promontory until we identify the lateral part of superior hypogastric plexus and then the inferior hypogastric nerve that descends 8–10 cm along the lateral sides of mesorectum, following the ureteral course in a dorsal and caudal direction. The next step is preparation of the nerve towards

uterine artery removing the inferior hypogastric nerve away from uterosacral ligament. At this point, inferior hypogastric nerve appears 2–3 cm dorsally to the ureter, in the lateral part of the uterosacral ligament.

Before making the colpotomy, we also create a vaginal cuff to enclose the cervix and upper part of the vagina, avoiding any contact with the abdominal cavity. After meticulous dissection of vaginal wall, we use 4–6 straight Kocher clamps to grasp circumferentially the mobilized vaginal wall. Thereby we create a vaginal cuff that totally overlaps the cervix and tumor, closing it with by continuous running suture between ventral and dorsal vaginal wall.

After that, we continue with radical resection of the cardinal and uterosacral ligaments and the operation is completed laparoscopically, without any contact of the primary tumor with the abdominal cavity. The colpotomy is made laparoscopically using scissors, while the surgeon has his left index finger in the vagina, as we have previously described [22], to identify the proper incision plane.

Postoperatively, we use no suprapubic catheter and only transurethral catheter that is removed on second postoperative day.

Patients follow-up was updated in the fourth quarter of 2019 and the first quarter of 2020.

Statistical analysis

Statistical analysis was conducted using Statistical Package for the Social Sciences (SPSS) release 23. For the patients' characteristics and surgical outcomes, mean values and range were calculated and for the recurrence rate and overall survival the Kaplan–Meier method. Median follow-up was determined coding events as censored and censored cases as events in a Kaplan–Meier analysis. Progression-Free Survival (PFS) curves were estimated by the Kaplan–Meier method while the population number at risk was calculated both for the complete population and the groups of women with stages IB1 and IB2 (Figo stage 2009).

Results

In the study period, 65 patients with cervical cancer were treated in our department. In Fig. 1, we present a flowchart of patients treated in our department. We selected 32 patients with Figo stage (2009) IB that underwent a type C laparoscopic radical hysterectomy.

In Table 1, we report all main patients' characteristics and surgical results and oncological characteristics. Out of the 27 patients with stage IB1, 18 were with tumor size 2–4 cm. The median age of patients was 50.5 years (range 31–68) and median body mass index (BMI) was 25.3 kg/m² (range 19–33.5 kg/m²). The average operating time was 228 min

(range 147–310 min) and median hospital stay was 2.7 days (range 2–7 days). Approximate blood loss was 188 ml (range 120–300 ml).

In all the cases, we had adequate number of lymph nodes as the minimum number of removed lymph nodes was 12 for pelvic lymph nodes and 11 for para-aortic. In three patients, pathology examination revealed positive pelvic lymph nodes with negative para-aortic, while in all the cases, we achieved clear vaginal margins without any parametrial involvement.

After a median follow-up of 37 months, we had 2 recurrences out of 32 cases and no death.

The Kaplan–Meier for the PFS estimates is presented in the same diagram (Fig. 2) for the complete population and separately for the IB1 and IB2 groups. The mean PFS measured time during this study for the complete population was 79.3 months (95% CI 74.1–84.5 months) for IB1 and 34.8 (95% CI 22.2–47.4 months) for IB2, while for the combined population 77.4 months (95% CI 71.1–83.6).

For the overall population, the 3-year PFS was 93.7% [number at risk 23 (71.8%)] and especially for the IB1 stage women, the 3-year PFS was 96.1% [number at risk 21 (77.7%)]. Concerning overall survival, the 3-year OS was 100% with no. at risk 71.8%.

The multidisciplinary tumor board of St. Luke's hospital decided that 13 patients had to receive adjuvant therapy according to NCCN treatment guidelines and Sedlis criteria for pelvic radiation therapy [23, 24]. More specifically, ten women received external beam radiotherapy (EBRT) and three women combined chemotherapy and radiotherapy.

The two recurrences were 1 central (vaginal vault), 12 months after surgery, in a patient with initial-stage IB1 (tumor size 2.9 cm). The woman was re-operated and received platinum-based chemotherapy combined with radiotherapy and is now disease free for 36 months. The other recurrence was in lateral pelvic wall (bladder–ureter), 5 months after surgery in a patient with initial-stage IB2 (tumor size 6.2 cm) that was decided to be treated with combined chemotherapy and radiotherapy and now is disease free for 12 months.

Discussion

Until now, it is well proved that minimally invasive (MIS) reveals equal oncological outcomes in patients with endometrial and colorectal cancer in big well-designed RCTs [25–27]. However, the anatomy and biology of endometrial and cervical cancer differ considerably; especially the risk of contaminating the peritoneal cavity with tumor cell, using manipulator in cervical cancer is much higher [17].

In the past decade, many studies have shown the feasibility of the laparoscopic radical hysterectomy, but much less was known about the DFS and OS rates and their association

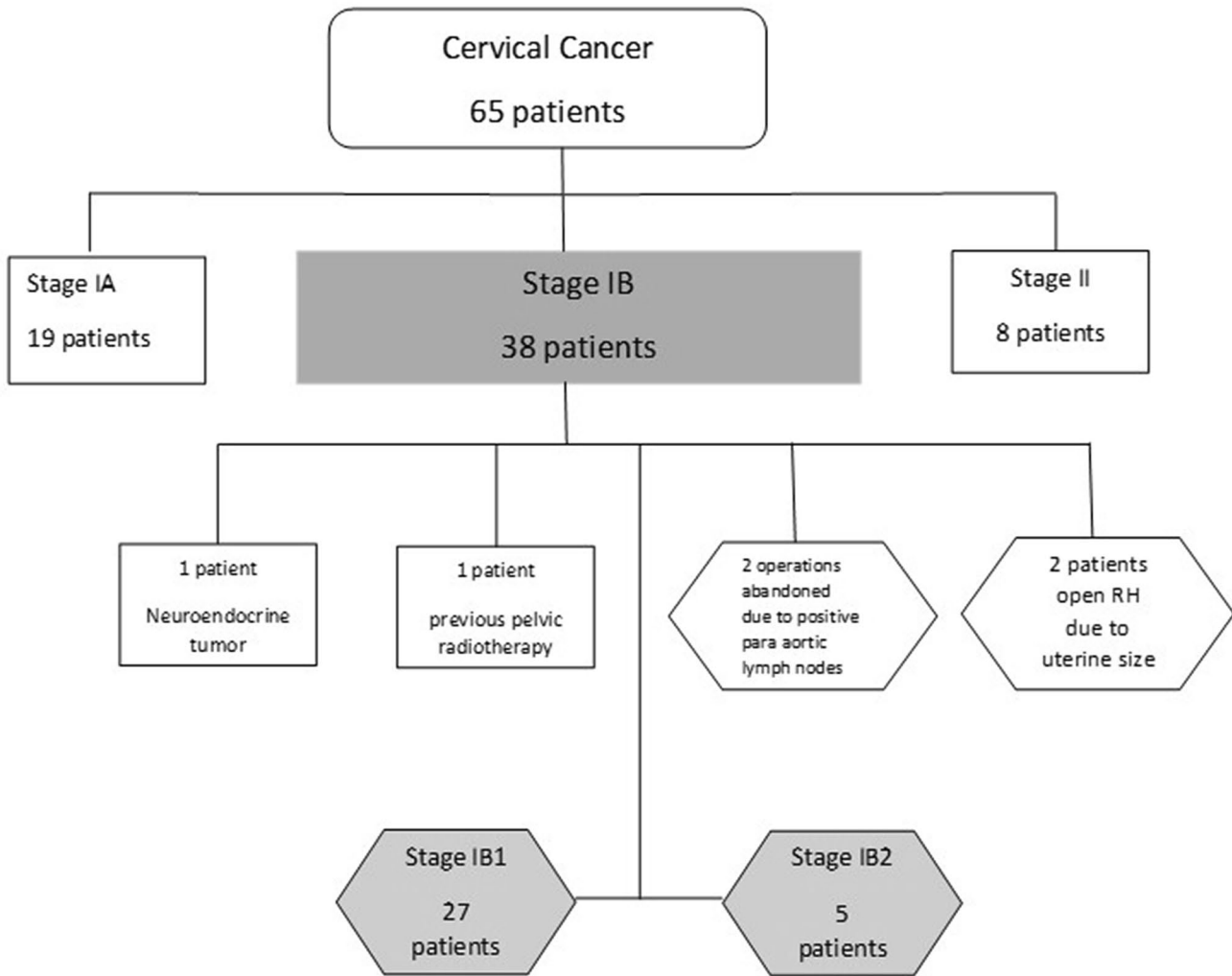


Fig. 1 Flowchart of patient selection

with a questionable radicality of the procedure [28–31]. The majority of the studies reported retrospective reviews showing intraoperative and postoperative data, and some of them confirmed the safety of the procedure in the hands of experienced laparoscopic surgeons in gynecologic oncology [32].

Traditional techniques of minimal invasive radical hysterectomy (laparoscopic as well as robotic radical hysterectomy) are usually associated with the use of uterine manipulator [33–35]. Manipulator was routinely used even in patients with macroscopically visible tumor, by squeezing and disrupting the tumor that is against the basic principles of an oncologic surgery. Opening the vaginal cuff above the manipulator rim, using simultaneously high CO₂ pressure, may cause tumor cells spread within the peritoneal cavity. The laparoscopic radical hysterectomy must be equal to the open procedure according the parametrial resection, resection in tumor-free margins, careful tumor manipulation and avoidance of tumor cell spillage [17, 18].

Recent publication of LACC trial [36] was a huge blow on laparoscopic management of cervical cancer worldwide, as oncological centers and surgeons had to reevaluate their surgical approach for radical hysterectomy. Of course a Randomized Control Trial (RCT) has the highest possible level of statistical significance, but even for this, RCT objections were raised for the followed surgical technique and whether surgical safety was ensured [14, 18].

After publication of LACC trial, more retrospective studies were published comparing MIS radical hysterectomy with open radical hysterectomy and they all revealed worst oncological outcome for the MIS arm [12–16].

In Table 2, we present the most important studies on radical hysterectomy comparing MIS and open surgery [11–17, 35, 37–40].

There is only a recent study by Kohler et al. [17] on laparoscopic radical hysterectomy without uterine manipulator, and both DFS and OS are remarkably higher compared to

Table 1 Patient's characteristics and surgical results

Age		50.5 (31–68) years
BMI		25.3 (19–33.5) kg/m ²
Operating time		228 (147–310) min
Hospital stay		2.7 (2–7) days
Blood loss		188 (120–300) ml
Stage	IB1	27 (18 cases: tumor size 2–4 cm)
	IB2	5
Grade	1	1 (3.12%)
	2	18 (56.25%)
	3	13 (40.62%)
Histologic type	Squamous	23 (71.87%)
	Adeno	8 (25%)
	Adeno-squamous	1 (3.12%)
Invasion	Superficial	2 (6.25%)
	Middle	18 (56.25%)
	Deep	12 (37.5%)
LVSI	Negative	22 (68.75%)
	Positive	10 (31.25%)
Parametrial involvement	Negative	32 (100%)
	Positive	0
Vaginal margins	Negative	32 (100%)
	Positive	0
Lymph nodes	Pelvic	28.5 (12–82)
	Para-aortic	17.8 (11–40)
	Positive pelvic	3 pts (9.375%)
Tumor size		2.88 (1.1–7) cm
Major intraoperative complications		0
Adjuvant therapy	EBRT or RCT	13 (40.63%)
	EBRT	10 (31.25%)
	RCT	3 (9.375%)
Follow-up		37 (6–82) months
Recurrences		2/32 (6.25%)
OS		32/32 (100%)
3-year PFS	IB ^a	93.7% (no. at risk 71.8%)
	IB1 ^a	96.1% (no. at risk 77.7%)
3-year OS		100% (no. at risk 71.8%)

BMI body mass index, LVSI lymphovascular space involvement, EBRT external beam radiotherapy, RCT combined radio-chemotherapy

^aFigo stage 2009

the other studies and MIS arm of LACC trial. Furthermore, only in this study a vaginal sealing of the tumor is reported before colpotomy, to avoid spillage of tumor cells. In all the other studies MIS approach was performed using uterine manipulator, without sealing vaginally the tumor before colpotomy.

Our approach on laparoscopic radical hysterectomy showed an excellent overall survival rate of 100% and 3-year PFS for stage IB 93.7% and for stage IB1 (2009) 96.1%. These data are in agreement with the published data by Kohler et al. [17] that they also did not use manipulator and sealed the tumor before colpotomy. Our outcomes, despite

the two recurrences, are even more satisfactory taking into consideration that in our study are included five cases of tumors bigger than 4 cm and one recurrence was among these patients.

In our opinion, MIS remains an option, under strict selection, for early cervical cancer and the worst oncological outcomes of MIS is due to the use of uterine manipulator and the spillage of tumor cells during the vagina opening. We had concerns for the use of uterine manipulator many years ago and from 2010, we have published our technique for laparoscopic nerve-sparing radical hysterectomy without uterine manipulator [19]. We also use

Fig. 2 Kaplan–Meier curve for PFS probability estimation for the complete population and in relation to the tumor stage

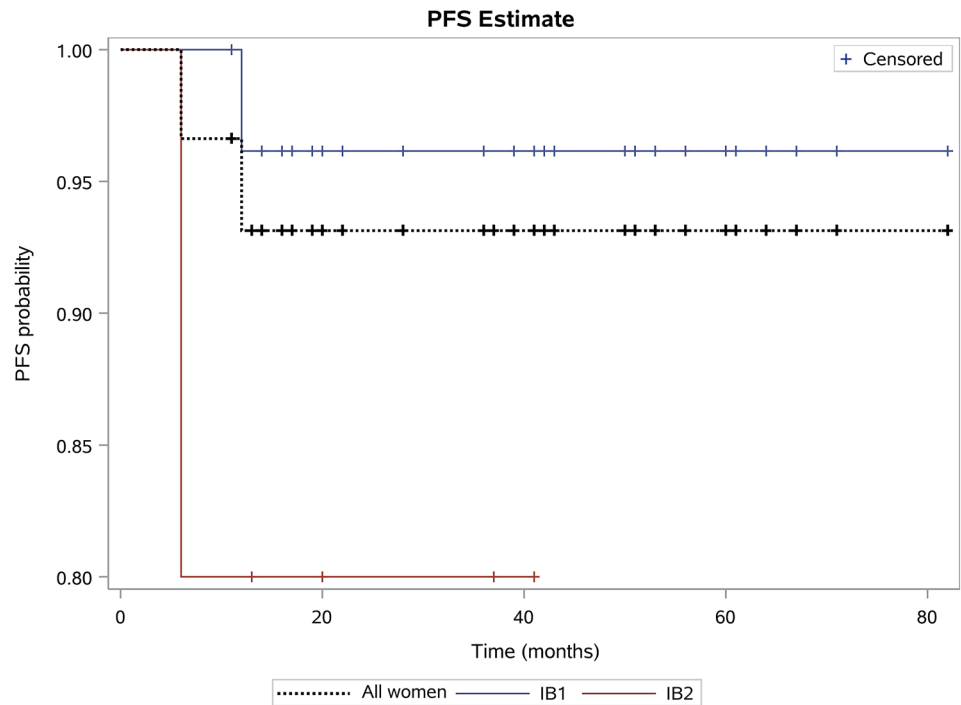


Table 2 Comparison of disease-free and overall survival

	Type	Number of pts	5-year DFS	5-year OS	Study design	Manipulator	Tumor sealing
Bogani et al. [38]	Laparoscopic	65	83%	89%	RCT	Yes	No
	Open	65	80%	83%			
Ditto et al. [39]	Laparoscopic	60	96.7%		RCT	Yes	No
	Open	60	91.6%				
Malzoni et al. [35]	Laparoscopic	65	92.4%		RCT	Yes	No
	Open	62	93.6%				
Nam et al. [40]	Laparoscopic	263	92.8%		RCT	Yes	No
	Open	263	94.4%				
Toptas et al. [37]	Laparoscopic	22	86.4%		RCT	Yes	No
	Open	46	91.1%				
LACC trial [11]	MIS	319	86% (4.5 years)	93.8% (3 years)	RCT	Yes	No
	Open	312	96.5 (4.5 years)	99% (3 years)			
Melamed et al. [15]	Minimally invasive	1225		90.9% (4 years)	Retrospective	Yes	No
	Open	1236		92.5% (4 years)			
Uppal et al. [12]	MIS	560	90.9%		Retrospective	Yes	No
	Open	255	92.5%				
Doo et al. [13]	MIS	49	70%	85%	Retrospective	Yes	No
	Open	56	92%	95%			
Kim et al. [14]	MIS	343	85.4%	96.9	Retrospective	Yes	No
	Open	222	91.8%	94.6%			
Cusimano et al. [16]	MIS	475	83.8%	92.7%	Retrospective	Yes	No
	Open	483	91.6%	96.7%			
Kohler et al. [17]	Laparoscopic	389	95.7%	97.6%	Retrospective	No	Yes
Our data	Laparoscopic	32	93.7%	100%	Retrospective	No	Yes

constantly 12 mm Hg CO₂ pressure, trying to minimize possible spread of cancer cells.

We believe that another crucial factor for this good outcome is that all the operations were performed by the same surgical team (A.K and D.Z) in a standardized way. A.K. has an experience for more than 10 years in performing laparoscopic radical hysterectomies and has performed laparoscopically more than 100 cases. D.Z had a 3-year training in gynecologic oncology, was trained by A.K and has performed under the surveillance of A.K 12 laparoscopic radical hysterectomies. On the other hand, the minimum requirement in LACC trial was ten operations. This is a very small number to consider efficient a laparoscopic surgeon for radical hysterectomy. Laparoscopic radical hysterectomy is very complex surgical procedure with a very long learning curve and as it is previously reported that for adequate surgical and radicality, minimum 40 cases are required [41–43]. We admit that a laparoscopic radical hysterectomy is more difficult without uterine manipulator, but in our mind, this is the only way in the future.

Our study has though many limitations and drawbacks. It is a retrospective single-center non-randomized study with a small number of patients. However, all the surgeries were performed in a standardized technique, without using uterine manipulator and with vaginal sealing of the tumor before colpotomy. Another advantage of our data is the median follow-up of 37 months and the very high percentage of data completeness.

Conclusion

The results of LACC trial and the following retrospective studies showed worse oncological outcome in MIS approach compared to open radical hysterectomy. In all these studies, uterine manipulator was used during the operation and no special precaution was taken for the tumor sealing. Our data show that laparoscopic nerve-sparing radical hysterectomy is feasible and safe without using uterine manipulator for stage IB cervical cancer, in the hands of well-trained and experienced laparoscopic surgeons. Moreover, vaginal tumor sealing may be another crucial factor affecting oncological outcome. Our findings are in agreement with another previously published retrospective study and show better PFS and OS compared to studies where manipulator was used and the tumor was not sealed. Of course, further randomized studies are necessary to evaluate outcomes of laparoscopic nerve-sparing radical hysterectomy performed without manipulator and with tumor sealing compared to open radical hysterectomy.

Author contributions AK: conceptualization, investigation; responsible surgeon; methodology; writing—original draft; and supervision. NC: data curation; formal analysis; writing—review and editing. AG: data curation; formal analysis, writing—review and editing. DZ: investigation; responsible surgeon; methodology; writing—original draft; and supervision.

Funding No funding was obtained for this study.

Compliance with ethical standards

Conflict of interest All the authors declare no conflict of interest.

Ethics approval Ethical approval was waived by the local Ethics Committee of the Hospital in view of the retrospective nature of the study and all the procedures being performed were part of the routine care.

Informed consent Informed consent was obtained from all the individual participants included in the study. Consent to publish: patients signed informed consent regarding publishing their data and photographs.

References

1. Arbyn M, Autier P, Ferlay J (2007) Burden of cervical cancer in the 27 member states of the European Union: estimates for 2004. *Ann Oncol* 18(8):1423–1425
2. Malcolm JD (1912) Wertheim's operation for cancer of the cervix uteri. *BMJ* 1(2685):1350–1354
3. Fujii S (2008) Original film of the Okabayashi's radical hysterectomy by Okabayashi himself in 1932, and two films of the precise anatomy necessary for nerve-sparing Okabayashi's radical hysterectomy clarified by Shingo Fujii. *Int J Gynecol Cancer* 18(2):383–385
4. Meigs JV (1951) Radical hysterectomy with bilateral pelvic lymph node dissections; a report of 100 patients operated on five or more years ago. *Am J Obstet Gynecol* 62(4):854–870
5. Piver MS, Rutledge F, Smith JP (1974) Five classes of extended hysterectomy for women with cervical cancer. *Obstet Gynecol* 44(2):265–272
6. Diver E, Hinchcliff E, Gockley A, Melamed A, Contrino L, Feldman S et al (2017) Minimally invasive radical hysterectomy for cervical cancer is associated with reduced morbidity and similar survival outcomes compared with laparotomy. *J Minim Invasive Gynecol* 24(3):402–406
7. Long Y, Yao DS, Pan XW, Ou TY (2014) Clinical efficacy and safety of nerve-sparing radical hysterectomy for cervical cancer: a systematic review and meta-analysis. *PLoS ONE* 9(4):e94116
8. Kavallaris A, Zygouris D, Dafopoulos A, Kalogiannidis I, Terzakis E (2015) Nerve sparing radical hysterectomy in early stage cervical cancer. Latest developments and review of the literature. *Eur J Gynaecol Oncol*. 36(1):5–9
9. Sert BM, Boggess JF, Ahmad S, Jackson AL, Stavitzski NM, Dahl AA et al (2016) Robot-assisted versus open radical hysterectomy: a multi-institutional experience for early-stage cervical cancer. *Eur J Surg Oncol* 42(4):513–522
10. Shazly SA, Murad MH, Dowdy SC, Gostout BS, Famuyide AO (2015) Robotic radical hysterectomy in early stage cervical cancer: a systematic review and meta-analysis. *Gynecol Oncol* 138(2):457–471
11. Ramirez PT, Frumovitz M, Pareja R, Lopez A, Vieira M, Ribeiro R et al (2018) Minimally invasive versus

- abdominal radical hysterectomy for cervical cancer. *N Engl J Med* 379(20):1895–1904
12. Uppal S, Gehrig PA, Peng K, Bixel KL, Matsuo K, Vetter MH et al (2020) Recurrence rates in patients with cervical cancer treated with abdominal versus minimally invasive radical hysterectomy: a multi-institutional retrospective review study. *J Clin Oncol* 38(10):1030–1040
 13. Doo DW, Kirkland CT, Griswold LH, McGwin G, Huh WK, Leath CA 3rd et al (2019) Comparative outcomes between robotic and abdominal radical hysterectomy for IB1 cervical cancer: results from a single high volume institution. *Gynecol Oncol* 153(2):242–247
 14. Kim SI, Lee M, Lee S, Suh DH, Kim HS, Kim K et al (2019) Impact of laparoscopic radical hysterectomy on survival outcome in patients with FIGO stage IB cervical cancer: a matching study of two institutional hospitals in Korea. *Gynecol Oncol* 155(1):75–82
 15. Melamed A, Margul DJ, Chen L, Keating NL, Del Carmen MG, Yang J et al (2018) Survival after minimally invasive radical hysterectomy for early-stage cervical cancer. *N Engl J Med* 379(20):1905–1914
 16. Cusimano MC, Baxter NN, Gien LT, Moineddin R, Liu N, Dossa F et al (2019) Impact of surgical approach on oncologic outcomes in women undergoing radical hysterectomy for cervical cancer. *Am J Obstet Gynecol* 221(6):619e1–24
 17. Kohler C, Hertel H, Herrmann J, Marnitz S, Mallmann P, Favero G et al (2019) Laparoscopic radical hysterectomy with transvaginal closure of vaginal cuff—a multicenter analysis. *Int J Gynecol Cancer* 29(5):845–850
 18. Kohler C, Schneider A, Marnitz S, Plaikner A (2020) The basic principles of oncologic surgery during minimally invasive radical hysterectomy. *J Gynecol Oncol* 31(1):e33
 19. Kavallaris A, Hornemann A, Chalvatzas N, Luedders D, Diedrich K, Bohlmann MK (2010) Laparoscopic nerve-sparing radical hysterectomy: description of the technique and patients' outcome. *Gynecol Oncol* 119(2):198–201
 20. Cibula D, Abu-Rustum NR, Benedetti-Panici P, Kohler C, Raspagliesi F, Querleu D et al (2011) New classification system of radical hysterectomy: emphasis on a three-dimensional anatomic template for parametrial resection. *Gynecol Oncol* 122(2):264–268
 21. Kavallaris A, Kalogiannidis I, Chalvatzas N, Hornemann A, Bohlmann MK, Diedrich K (2011) Standardized technique of laparoscopic pelvic and para-aortic lymphadenectomy in gynecologic cancer optimizes the perioperative outcomes. *Arch Gynecol Obstet* 283(6):1373–1380
 22. Zygouris D, Chalvatzas N, Gkoutzioulis A, Anastasiou G, Kavallaris A (2020) Total laparoscopic hysterectomy without uterine manipulator. A retrospective study of 1023 cases. *Eur J Obstet Gynecol Reprod Biol.* 253:254–258
 23. Koh WJ, Abu-Rustum NR, Bean S, Bradley K, Campos SM, Cho KR et al (2019) Cervical cancer, Version 3. 2019, NCCN clinical practice guidelines in oncology. *J Natl Comprh Cancer Netw* 17(1):64–84
 24. Sedlis A, Bundy BN, Rotman MZ, Lentz SS, Mudderspach LI, Zaino RJ (1999) A randomized trial of pelvic radiation therapy versus no further therapy in selected patients with stage IB carcinoma of the cervix after radical hysterectomy and pelvic lymphadenectomy: a gynecologic oncology group study. *Gynecol Oncol* 73(2):177–183
 25. Clinical Outcomes of Surgical Therapy Study G, Nelson H, Sargent DJ, Wieand HS, Fleshman J, Anvari M et al (2004) A comparison of laparoscopically assisted and open colectomy for colon cancer. *N Engl J Med* 350(20):2050–2059
 26. Lacy AM, Garcia-Valdecasas JC, Delgado S, Castells A, Taura P, Pique JM et al (2002) Laparoscopy-assisted colectomy versus open colectomy for treatment of non-metastatic colon cancer: a randomised trial. *Lancet* 359(9325):2224–2229
 27. Walker JL, Piedmonte MR, Spirtos NM, Eisenkop SM, Schlaerth JB, Mannel RS et al (2012) Recurrence and survival after random assignment to laparoscopy versus laparotomy for comprehensive surgical staging of uterine cancer: gynecologic Oncology Group LAP2 Study. *J Clin Oncol* 30(7):695–700
 28. Frumovitz M, dos Reis R, Sun CC, Milam MR, Bevers MW, Brown J et al (2007) Comparison of total laparoscopic and abdominal radical hysterectomy for patients with early-stage cervical cancer. *Obstet Gynecol* 110(1):96–102
 29. Abu-Rustum NR, Gemignani ML, Moore K, Sonoda Y, Venkatraman E, Brown C et al (2003) Total laparoscopic radical hysterectomy with pelvic lymphadenectomy using the argon-beam coagulator: pilot data and comparison to laparotomy. *Gynecol Oncol* 91(2):402–409
 30. Pellegrino A, Damiani GR, Tartagni M, Speciale D, Villa M, Sportelli C et al (2013) Isobaric laparoscopy using LaparoTenser system in surgical gynecologic oncology. *J Minimally Invasive Gynecol* 20(5):686–690
 31. Malur S, Possover M, Schneider A (2001) Laparoscopically assisted radical vaginal versus radical abdominal hysterectomy type II in patients with cervical cancer. *Surg Endosc* 15(3):289–292
 32. Malzoni M, Tinelli R, Cosentino F, Perone C, Vicario V (2007) Feasibility, morbidity, and safety of total laparoscopic radical hysterectomy with lymphadenectomy: our experience. *J Minimally Invasive Gynecol* 14(5):584–590
 33. Canton-Romero JC, Anaya-Prado R, Rodriguez-Garcia HA, Mejia-Romo F, De-Los-Rios PE, Cortez-Martinez G et al (2010) Laparoscopic radical hysterectomy with the use of a modified uterine manipulator for the management of stage IB1 cervix cancer. *J Obstet Gynaecol* 30(1):49–52
 34. Spirtos NM, Eisenkop SM, Schlaerth JB, Ballon SC (2002) Laparoscopic radical hysterectomy (type III) with aortic and pelvic lymphadenectomy in patients with stage I cervical cancer: surgical morbidity and intermediate follow-up. *Am J Obstet Gynecol* 187(2):340–348
 35. Malzoni M, Tinelli R, Cosentino F, Fusco A, Malzoni C (2009) Total laparoscopic radical hysterectomy versus abdominal radical hysterectomy with lymphadenectomy in patients with early cervical cancer: our experience. *Ann Surg Oncol* 16(5):1316–1323
 36. Ramirez PT, Obermair A (2019) Minimally invasive or abdominal radical hysterectomy for cervical cancer. Reply. *N Engl J Med* 380(8):794–795
 37. Toptas T, Simsek T (2014) Total laparoscopic versus open radical hysterectomy in stage IA2-IB1 cervical cancer: disease recurrence and survival comparison. *J Laparoendosc Adv Surg Tech Part A* 24(6):373–378
 38. Bogani G, Cromi A, Uccella S, Serati M, Casarin J, Pinelli C et al (2014) Laparoscopic versus open abdominal management of cervical cancer: long-term results from a propensity-matched analysis. *J Minimally Invasive Gynecol* 21(5):857–862
 39. Ditto A, Martinelli F, Bogani G, Gasparri ML, Di Donato V, Zanaboni F et al (2015) Implementation of laparoscopic approach for type B radical hysterectomy: a comparison with open surgical operations. *Eur J Surg Oncol* 41(1):34–39
 40. Nam JH, Park JY, Kim DY, Kim JH, Kim YM, Kim YT (2012) Laparoscopic versus open radical hysterectomy in early-stage cervical cancer: long-term survival outcomes in a matched cohort study. *Ann Oncol* 23(4):903–911
 41. Park JY, Nam JH (2018) How should gynecologic oncologists react to the unexpected results of LACC trial? *J Gynecol Oncol* 29(4):e74
 42. Hwang JH, Yoo HJ, Joo J, Kim S, Lim MC, Song YJ et al (2012) Learning curve analysis of laparoscopic radical hysterectomy

and lymph node dissection in early cervical cancer. *Eur J Obstet Gynecol Reprod Biol* 163(2):219–223

43. Chong GO, Park NY, Hong DG, Cho YL, Park IS, Lee YS (2009) Learning curve of laparoscopic radical hysterectomy with pelvic and/or para-aortic lymphadenectomy in the early and locally advanced cervical cancer: comparison of the first 50 and second 50 cases. *Int J Gynecol Cancer* 19(8):1459–1464

Publisher's Note Springer Nature remains neutral with regard to jurisdictional claims in published maps and institutional affiliations.