

# CLINICAL AND EXPERIMENTAL OBSTETRICS & GYNECOLOGY

an International Journal

*Founding Editor*

**A. Onnis**  
*Montréal (CND)*

*Editors-in-Chief*

**M. Marchetti**      **J.H. Check**  
*Montréal (CND)*      *Camden, NJ (USA)*

*Assistant Editor*

**A. Sinopoli**  
*Toronto (CND)*

*Editorial Board*

Audet-Lapointe P., <i>Montréal (Canada)</i>	Gorins A., <i>Paris (France)</i>
Axt-Fliedner R., <i>Lübeck (Germany)</i>	Grella P.V., <i>Padua (Italy)</i>
Basta A., <i>Krakow (Poland)</i>	Holub Z., <i>Kladno (Czech Republic)</i>
Bender H.J., <i>Dusseldorf (Germany)</i>	Jordan J.A., <i>Birmingham, England (UK)</i>
Bhattacharya N., <i>Calcutta (India)</i>	Kaplan B., <i>Petach Tikva (Israel)</i>
Bonilla Musoles F., <i>Valencia (Spain)</i>	Markowska J., <i>Poznan (Poland)</i>
Cabero-Roura L., <i>Barcelona (Spain)</i>	Marth C., <i>Innsbruck (Austria)</i>
Charkviani T., <i>Tbilisi (Georgia)</i>	Meden-Vrtovec H., <i>Ljubljana (Slovenia)</i>
Dexeus S., <i>Barcelona (Spain)</i>	Murta E.F.C., <i>Uberaba (Brasil)</i>
Di Paola G., <i>Buenos Aires (Argentina)</i>	Papadopoulos N., <i>Alexandroupolis (Greece)</i>
Eskes T.K.A.B., <i>Nijmegen (The Netherlands)</i>	Rakar S., <i>Ljubljana (Slovenia)</i>
Farghaly S.A., <i>New York (USA)</i>	Rigó J., <i>Budapest (Hungary)</i>
Friedrich M., <i>Homburg (Germany)</i>	Sciarra J.J., <i>Chicago, IL (USA)</i>
Gomel V., <i>Vancouver (Canada)</i>	Stelmachow J., <i>Warsaw (Poland)</i>
	Varras M.N., <i>Athens (Greece)</i>
	Winter R., <i>Graz (Austria)</i>

*Publishing Organization (M. Beaucage):*

7847050 CANADA, Inc. - 4900 Côte St-Luc - Apt # 212 - Montréal, Qué. H3W 2H3 (Canada)  
Tel. +514-4893242 - Fax +514-4854513 - E-mail: canlux@mgroun-online.com - www.irog.net

*Editorial Office (M. Critelli):*

Galleria Storione, 2/A - 35123 Padua (Italy) - Tel. (39) 049 8756900 - Fax (39) 049 8752018  
e-mail: irog@onnisanantonio.191.it

CLINICAL AND EXPERIMENTAL OBSTETRICS AND GYNECOLOGY (ISSN 0390-6663) publishes original work, preferably brief reports, in the fields of Gynecology, Obstetrics, Fetal Medicine, Gynecological Endocrinology and related subjects. (Fertility and Sterility, Menopause, Uro-gynecology, Ultrasound in Obstetrics and Gynecology, Sexually Transmitted Diseases, Reproductive Biological Section). The Journal is covered by **INDEX MEDICUS, MEDLINE, EMBASE/Excerpta Medica, PUD MED.**

CLINICAL AND EXPERIMENTAL OBSTETRICS AND GYNECOLOGY is issued every three months in one volume per year by 7847050 CANADA Inc. Montréal. Printed in Italy by "La Garangola", Tipografia Editrice - Via E. Dalla Costa, 6 - 35129 Padova (Italy).

<b>Ultrasound diagnosis of recurring Jeune's syndrome: a case report</b>	162
E.N. Kontomanolis, E. Markopoulou, P. Pinidis, A. Georgiadis, S. Kokkoris, V. Limperis - <i>Alexandroupolis, GREECE</i>	
A case report of two successive pregnancies with Jeune's Syndrome, which is a rare skeletal dysplasia associated with multiple organ anomalies is presented.	
<b>Benign pelvic metastatic leiomyoma: case report</b>	165
H. Wei, Y. Liu, H. Sun, F. Qian, G. Li - <i>Beijing, CHINA</i>	
A case of pelvic BML, who underwent surgical resection four years ago and recovered well is reported.	
<b>Pyomyoma after dilatation and curettage for missed abortion</b>	168
F.G. Ugurlucan, A.C. Iyibozkurt, S. Sen, O. Kuru, S. Berkman - <i>Istanbul, TURKEY</i>	
Broad spectrum antibiotics and myomectomy was the therapy for a patient with pyomyoma after curettage for missed abortion.	
<b>The management of fusion of the labia minora pudendi in adult women using a radiosurgical knife</b>	170
M. Prorocic, M. Vasiljevic, L. Tasic, O. Džatić, S. Brankovic - <i>Belgrade, SERBIA</i>	
A successful case of knife radiosurgical procedure in patients with fusion of the pudenda labia minora is reported.	
<b>Spontaneous rupture of uterine varices in third trimester pregnancy: an unexpected cause of hemoperitoneum. A case report and literature review</b>	175
K.L.P. Nguessan, D.B. Mian, G.A. Aissi, C. Oussou, S. Boni - <i>Abidjan, IVORY COAST</i>	
A rare case of hemoperitoneum during the third trimester of pregnancy due to varices spontaneous rupture is reported.	
<b>Laparoscopic myomectomy of a giant myoma</b>	178
A. Kavallaris, D. Zygouris, N. Chalvatzas, E. Terzakis - <i>Athens, GREECE</i>	
The case of an infertile woman with a 18-cm uterine myoma which was laparoscopically removed is presented.	

# Laparoscopic myomectomy of a giant myoma

A. Kavallaris<sup>1,2</sup>, D. Zygouris<sup>3</sup>, N. Chalvatzas<sup>1</sup>, E. Terzakis<sup>3</sup>

<sup>1</sup>4th Department of Gynecology and Obstetrics, Aristotle University of Thessaloniki, Thessaloniki

<sup>2</sup>Department of Gynecologic Oncology, St. Loukas Hospital, Thessaloniki

<sup>3</sup>2nd Department of Gynecology, St. Savvas Anticancer-Oncological Hospital, Athens (Greece)

## Summary

We present the case of an infertile woman with a giant myoma which was laparoscopically removed. A 34-year-old patient was referred to our department with a large abdominal mass. Ultrasound revealed an 18 cm uterine myoma. Diagnostic laparoscopy showed a giant uterine myoma and with the help of a bent angle camera we started myoma enucleation. The myoma was totally enucleated and removed without disturbing the endometrial cavity. The uterine defect was closed with an absorbable suture in two layers. The myoma was removed using a PK (Gyrus) morcelator, without tissue or blood spillage in the abdomen. The operation time was 165 minutes and the myoma's weight was 1,200 g. The patient recovered uneventfully. Laparoscopic myomectomy can be an option even for giant myomas, with the condition of an expert surgeon and appropriate surgical instruments.

*Key words:* Laparoscopic myomectomy; Giant myoma.

## Introduction

Laparoscopic myomectomy is a minimal invasive method for management of myomas in women of reproductive age. It offers several advantages, such as shorter hospitalization, faster recovery, fewer adhesions, and less blood loss [1-3]. The main problem is that advanced laparoscopic technical skills are required to perform laparoscopic myomectomy [4]. As a result the procedure is used more frequently for small- and medium-sized myomas [5-8] and there are only a few series of myomectomies for large myomas [9, 10]. We report the case of a 34-year-old patient with a giant myoma who underwent total laparoscopic myomectomy.

## Case Report

A 34-year-old nulliparous patient was referred to our department with a large abdominal mass. Bimanual examination revealed a mass which extended from the pelvis up to the abdomen. Abdominopelvic ultrasonography showed an uterine myoma measuring 18 x 10 cm in size. The sonographic appearance of the mass aroused no suspicion of malignancy and the serum concentration of CA-125 was within normal limits.

Written informed consent was obtained from the patient and diagnostic laparoscopy was performed under general anesthesia. The patient was placed in a modified lithotomy position. A foley catheter was inserted and no uterine manipulator was used. Carbon dioxide was insufflated through a Veress needle through the Pulmer's point. The first assistant held a bent angle camera for better surgical vision in his left hand and grasping forceps in his right (Figure 1). The operator enucleated and removed the myoma without disturbing the endometrial cavity and the uterine defect was closed with an absorbable suture in two layers with intra corporeal knots (Figure 2). The myoma was then removed using a PK (Gyrus) morcelator, without tissue or blood spillage in the abdomen (Figure 3).

The operation time was 165 minutes and the myoma weighed 1,200 g. There was no need for blood transfusion intra- or post-operative and the estimated blood loss was 200 ml. The patient was mobilized the first postoperative day and the recovery was uneventful. The pathology report confirmed uterine myoma and the patient was advised that in case of a future pregnancy she should undergo a cesarean section.

## Discussion

Today there is a delay in the age of first pregnancy and consequently uterine preservation is necessary in even more cases of symptomatic myomas including large myomas.

Laparoscopic myomectomy using pneumoperitoneum is considered a procedure that requires experienced laparoscopic surgeons [11] and therefore it is not used widely for large myomas. Even though laparoscopic myomectomy offers a better cosmetic result, faster recovery and less postoperative adhesions, disagreement still exists concerning the usefulness of laparoscopic myomectomy for large myomas. It is suggested that the myomas size should not exceed 8 cm [12, 13]. There are reports that bigger myomas result in increased operative time and blood loss, and their cleavage is more difficult [14].

In this article a case of a very large myoma is presented which was successfully removed laparoscopically. As effective enucleation of the myoma is the most crucial step, a bent camera was used in order to improve the surgical vision because the myoma occupied the whole abdominal cavity. This camera afforded the opportunity to enucleate the myoma without bleeding, using bipolar diathermy. Special care was taken to minimize any thermal damage by coagulating under direct vision. There was no excessive blood loss, although this is considered a major problem for large myomas [15]. It is very important for the surgeon to have the appropriate instrumentation. A smart bipolar diathermy offers the best

Revised manuscript accepted for publication April 16, 2012

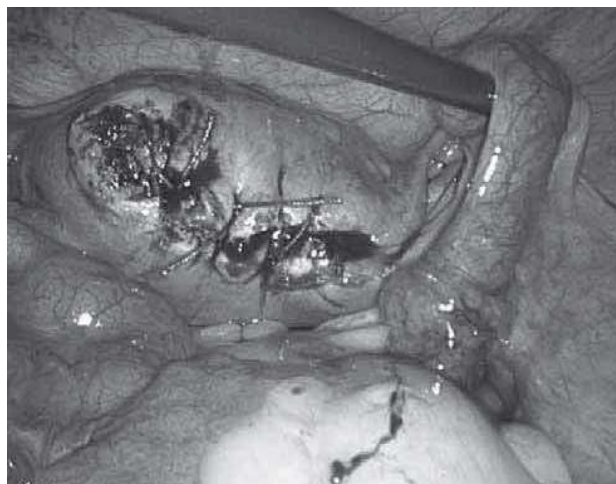
Fig. 1

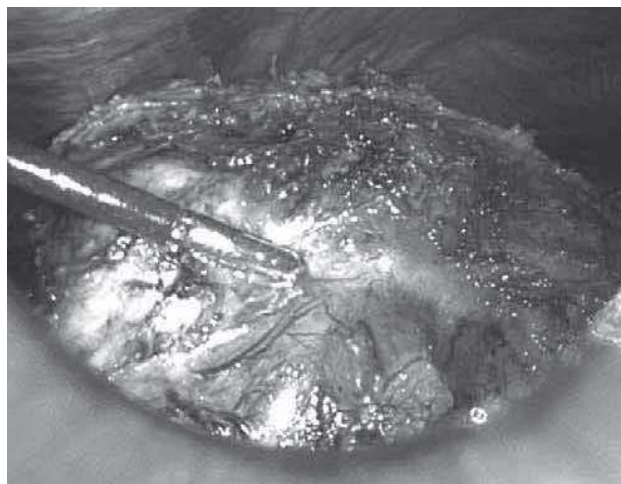

Fig. 3



Fig. 2



hemostasis by coagulation, minimizing the thermal damage on the uterus. Moreover the bent camera gives the opportunity to surgically approach areas that the surgeon would not be able to reach with a conventional camera.

The uterine incision was repaired in two layers for better integrity of the myometrium and hemostasis [11, 16]. A 2-0 absorbable suture performing intra corporeal knots was used. The final result was very satisfactory and the patient was advised to undergo a cesarean section in future pregnancy.

The operative time was 165 minutes and most the time was consumed for the removal of the myoma with a PK (Gyrus) morcelator. This morcelator has the advantage of no tissue or blood spillage in the abdomen, preventing from future adhesions and ensuring a better fertility result. It should also be mentioned that laparoscopy results in fewer adhesions than laparotomy with vertical incision which was our other choice.

The patient recovered uneventfully and was discharged the third day after the operation. She needed only paracetamol as painkillers and did not complain of any significant postoperative abdominal discomfort.

Figure 1. — Laparoscopic view of the giant myoma.

Figure 2. — Uterus after enucleation and laparoscopic suturing.

Figure 3. — Myoma removed by morcelator.

This satisfactory result can be explained by the advantages of laparoscopic myomectomy performed by an experienced surgeon. We believe that this is the best choice for fertility preservation even in cases of large myomas considering the other methods that have been proposed, such as mini-laparotomy [15, 17] or gasless laparoscopic myomectomy [18-21].

However further studies on extensive series are needed to better define the indications and long-term results.

## References

- [1] Hurst B.S., Matthews M.L., Marshburn P.B.: "Laparoscopic myomectomy for symptomatic uterine myomas". *Fertil. Steril.*, 2005, 83, 1.
- [2] Dubuisson J.B., Fauconnier A., Chapron C., Kreiker G., Nörgaard C.: "Second look after laparoscopic myomectomy". *Hum. Reprod.*, 1998, 13, 2102.
- [3] Mais V., Ajossa S., Guerriero S., Mascia M., Solla E., Melis G.B.: "Laparoscopic versus abdominal myomectomy: a prospective, randomized trial to evaluate benefits in early outcome". *Am. J. Obstet. Gynecol.*, 1996, 174, 654.
- [4] Alessandri F., Lijoi D., Mistrangelo E., Ferrero S., Ragni N.: "Randomized study of laparoscopic versus minilaparotomic myomectomy for uterine myomas". *J. Minim. Invasive Gynecol.*, 2006, 13, 92.

- [5] Dubuisson J.B., Fauconnier A., Deffarges J.V., Norgaard C., Kreiker G., Chapron C.: "Pregnancy outcome and deliveries following laparoscopic myomectomy". *Hum. Reprod.*, 2000, 15, 869.
- [6] Ribeiro S.C., Reich H., Rosenberg J., Guglielminetti E., Vidali A.: "Laparoscopic myomectomy and pregnancy outcome in infertile patients". *Fertil. Steril.*, 1999, 71, 571.
- [7] Rossetti A., Sizzi O., Soranna L., Cucinelli F., Mancuso S., Lanzone A.: "Long-term results of laparoscopic myomectomy: recurrence rate in comparison with abdominal myomectomy". *Hum. Reprod.*, 2001, 16, 770.
- [8] Rossetti A., Sizzi O., Soranna L., Mancuso S., Lanzone A.: "Fertility outcome: long-term results after laparoscopic myomectomy". *Gynecol. Endocrinol.*, 2001, 15, 129.
- [9] Seiner P., Arisio R., Decko A., Farina C., Crana F.: "Laparoscopic myomectomy: indications, surgical technique and complications". *Hum. Reprod.*, 1997, 12, 1927.
- [10] Adamian L.V., Kulakov V.I. VI, Kiselev S.I., Murashko A.V.: "Laparoscopic myomectomy in treatment of large myomas". *J. Am. Assoc. Gynecol. Laparosc.*, 1996, 3 (4 suppl.), S1.
- [11] Nezhat C., Nezhat F., Bess O., Nezhat C.H., Mashlach R.: "Laparoscopically assisted myomectomy: a report of a new technique in 57 cases". *Int. J. Fertil. Menopausal Stud.*, 1994, 39, 39.
- [12] Malzoni M., Rotond M., Perone C., Labriola D., Ammaturo F., Izzo A. et al.: "Fertility after laparoscopic myomectomy of large uterine myomas: operative technique and preliminary results". *Eur. J. Gynaecol. Oncol.*, 2003, 24, 79.
- [13] Takeuchi H., Kuwatsuru R.: "The indications, surgical techniques, and limitations of laparoscopic myomectomy". *JLS*, 2003, 7, 89.
- [14] Dubuisson J.B., Fauconnier A., Chapron C., Kreiker G., Norgaard C.: "Reproductive outcome after laparoscopic myomectomy in infertile women". *J. Reprod. Med.*, 2000, 45, 23.
- [15] Wang C.J., Yuen L.T., Lee C.L., Kay N., Soong Y.K.: "Laparoscopic myomectomy for large uterine fibroids. A comparative study". *Surg. Endosc.*, 2006, 20, 1427.
- [16] Ostrzenski A.: "A new laparoscopic myomectomy technique for intramural fibroids penetrating the uterine cavity". *Eur. J. Obstet. Gynecol. Reprod. Biol.*, 1997, 74, 189.
- [17] Wen K.C., Sung P.L., Lee W.L., Li Y.T., Su W.H., Wang P.H.: "Myomectomy for uterine myomas through ultramini-laparotomy". *J. Obstet. Gynaecol. Res.*, 2011, 37, 383.
- [18] Damiani A., Melgrati L., Franzoni G., Stepanyan M., Bonifacio S., Sesti F.: "Isobaric gasless laparoscopic myomectomy for removal of large uterine leiomyomas". *Surg. Endosc.*, 2006, 20, 1406.
- [19] Palomba S., Zupi E., Falbo A., Russo T., Marconi D., Zullo F.: "New tool (Laparotenser) for gasless laparoscopic myomectomy: a multicenter-controlled study". *Fertil. Steril.*, 2010, 94, 1090.
- [20] Damiani A., Melgrati L., Marziali M., Sesti F., Piccione E.: "Laparoscopic myomectomy for very large myomas using an isobaric (gasless) technique". *JLS*, 2005, 9, 434.
- [21] Sesti F., Capobianco F., Capozzolo T., Pietropolli A., Piccione E.: "Isobaric gasless laparoscopy versus minilaparotomy in uterine myomectomy: a randomized trial". *Surg. Endosc.*, 2008, 22, 917.

Address reprint requests to:  
D. ZYGOURIS, M.D.  
Dimitsanas Str. 40  
11522, Athens (Greece)  
e-mail: zyg14@hotmail.com