

# europaean journal of gynaecological oncology

an International Journal

*Founding Editor*

**A. Onnis**

*Montréal (Canada)*

*Editors-in-Chief*

**M. Marchetti**

*Montréal (Canada)*

**P. Bószé**

*Budapest (Hungary)*

*Associate Editor*

**T. Maggino**

*Padua (Italy)*

*Assistant Editor*

**A. Sinopoli**

*Toronto (Canada)*

*Editorial Board*

- |   |  |  |
|---|--|--|
| Allen H.H., <i>London, Ontario (Canada)</i>       | Geisler H.E., <i>Indianapolis, IN (USA)</i>                | Monsonogo J., <i>Paris (France)</i>        |
| Ayhan A., <i>Ankara (Turkey)</i>                  | Gorins A., <i>Paris (France)</i>                           | Pálfalvi L., <i>Budapest, (Hungary)</i>    |
| Balat O., <i>Graziantep (Turkey)</i>              | Heintz A.P.M.,<br><i>Utrecht (The Netherlands)</i>         | Piura B., <i>Beer Sheva (Israel)</i>       |
| Balega J., <i>Birmingham, England (UK)</i>        | Ioannidou-Mouzaka L.,<br><i>Athens (Greece)</i>            | Piver S.M., <i>Buffalo, NY (USA)</i>       |
| Băncăanu G., <i>Bucarest (Romania)</i>            | Jordan J.A.,<br><i>Birmingham, England (UK)</i>            | Rakar S., <i>Ljubljana (Slovenia)</i>      |
| Basta A., <i>Krakow (Poland)</i>                  | Klastersky J., <i>Bruxelles (Belgium)</i>                  | Shepherd J.H., <i>London, England (UK)</i> |
| Bender H.C., <i>Dusseldorf (Germany)</i>          | Kubista E., <i>Vienna (Austria)</i>                        | Siklòs P., <i>Budapest (Hungary)</i>       |
| Charkviani T., <i>Tbilisi (Georgia)</i>           | Lee Y.S., <i>Daegu (South Korea)</i>                       | Smit B.J., <i>Tygerberg (South Africa)</i> |
| Chiarelli S., <i>Padua (Italy)</i>                | Markowska J., <i>Poznan (Poland)</i>                       | Stelmachów J., <i>Warsaw (Poland)</i>      |
| De Oliveira C.F., <i>Coimbra (Portugal)</i>       | Mariani A., <i>Rochester, MN (USA)</i>                     | Syrjänen K., <i>Turku (Finland)</i>        |
| Dexeus S. Jr., <i>Barcelona (Spain)</i>           | Marth C., <i>Innsbruck (Austria)</i>                       | Tjalma W., <i>Antwerpen (Belgium)</i>      |
| Di Paola G.R.,<br><i>Buenos Aires (Argentina)</i> | Massuger Leon F.A.G.,<br><i>Nijmegen (The Netherlands)</i> | Ungár L., <i>Budapest (Hungary)</i>        |
| Di Re F., <i>Milan (Italy)</i>                    | Menczer J., <i>Savyon (Israel)</i>                         | Vermorken J.B., <i>Edegem (Belgium)</i>    |
| Di Saia P., <i>Orange, CA (USA)</i>               |  | Wang P.H., <i>Taipei (Taiwan)</i>          |
| Elit L., <i>Hamilton (Canada)</i>                 |  | Winter R., <i>Graz (Austria)</i>           |
| Friedrich M., <i>Krefeld (Germany)</i>            |  | Yokoyama Y., <i>Hirosaki (Japan)</i>       |

*Publishing Organization (M. Beaucage):*

7847050 CANADA, Inc. - 4900 Côte St-Luc - Apt # 212 - Montréal, Qué. H3W 2H3 (Canada)  
Tel. +514-4893242 - Fax +514-4854513 - E-mail: canlux@mgroup-online.com - www.irog.net

*Editorial Office (M. Critelli):*

Galleria Storione, 2/A - 35123 Padua (Italy) - Tel. (39) 049 8756900 - Fax (39) 049 8752018  
E-mail: irog@onnisanantonio.191.it

EUROPEAN JOURNAL OF GYNAECOLOGICAL ONCOLOGY (ISSN 0392-2936) publishes original peer reviewed works in the fields of female genital cancers and related subjects and also proceedings of gynecologic oncology society meetings all over the world. The Journal is covered by **CURRENT CONTENTS, SCISEARCH, RESEARCH ALERT, INDEX MEDICUS, MEDLINE, EMBASE/Excerpta Medica, CURRENT ADVANCES IN CANCER RESEARCH, BIOSIS.**

<b>Predictive factors of malignancy in patients with adnexal masses</b>	65
M. Terzic, J. Dotlic, I. Likic, N. Ladjevic, N. Brndusic, T. Mihailovic, S. Andrijasevic, I. Pilic, J. Bila - <i>Belgrade, SERBIA</i> The specificity and sensitivity of the risk factor for malignancy index in patients with adnexal masses are evaluated.	
<b>Decreased prevalence of high-risk human papillomavirus infection is associated with obesity</b>	70
U.S. Jung, J.S. Choi, J.H. Ko, J.H. Lee, S.Y. Park, S.H. Park - <i>Seoul, REPUBLIC OF KOREA</i> High-risk human papillomavirus infection was influenced by obesity, but a lower prevalence of infection was observed in obese women.	
<b>Characteristics and prognosis of ovarian metastatic tumors: review of a single-institution experience</b>	75
V. Ulker, C. Numanoglu, V. Alpay, O. Akbayir, I. Polat, A. Gedikbasi, A. Akca - <i>Istanbul, TURKEY</i> Clinicopathological characteristics and role of surgery in patients with ovarian metastasis are reviewed.	
<b>Effects of loop electrosurgical excision procedure or cold knife conization on pregnancy outcomes</b>	79
H.J. Guo, R.X. Guo, Y.L. Liu - <i>Zhengzhou, CHINA</i> Loop electrosurgical excision was relatively safe and should be priority in patients with CIN who want to preserve fertility.	
<b>Evaluation of osteopontin and CA125 in detection of epithelial ovarian carcinoma</b>	83
M. Milivojevic, V. Boskovic, J. Atanackovic, S. Milicevic, S. Razic, B. Kastratovic Kotlica - <i>Belgrade, SERBIA</i> Osteopontin is a good marker for diagnosis of ovarian cancer and its sensitivity is improved in combination with CA125.	
<b>CASE REPORTS</b>	
<b>Primary peritoneal low-grade serous carcinoma forming a mass in the colon mimicking a colonic primary carcinoma: a case report</b>	86
T.A. Tran, R.W. Holloway - <i>Orlando, Florida (USA)</i> A primary low-grade peritoneal serous carcinoma presented with symptoms of a rectosigmoid tumor, mimicking a primary colonic carcinoma.	
<b>Complete remission of recurrent and refractory ovarian cancers using weekly administration of bevacizumab and gemcitabine/oxaliplatin: report of two cases</b>	90
M. Takano, Y. Ikeda, K. Kudoh, T. Kita, N. Sasaki, Y. Kikuchi - <i>Saitama, JAPAN</i> Weekly bevacizumab and gemcitabine/oxaliplatin for ovarian cancers enabled complete remission of recurrent ovarian cancer.	
<b>Uterine malignant mixed Müllerian tumor after adjuvant tamoxifen treatment for breast cancer</b>	94
C. Grigoriadis, G. Androutopoulos, D. Zygouris, N. Arniogiannaki, E. Terzakis - <i>Athens, GREECE</i> Two cases of uterine mixed Müllerian tumors in patients undergoing tamoxifen therapy are presented.	
<b>Condyloma acuminata induces focal intense FDG uptake mimicking vaginal stump recurrence from uterine cervical cancer</b>	99
T. Kishimoto, S. Mabuchi, H. Kato, T. Kimura - <i>Osaka, JAPAN</i> Condyloma acuminata in a patient treated for uterine cervical cancer may induce a suspect of vaginal recurrence as in this reported case.	
<b>Atypical polypoid adenomyoma mixed with endometrioid carcinoma: a case report</b>	101
L. Nejković, V. Pažin, D. Filimonović - <i>Belgrade, SERBIA</i> A case of fertility preservation in a patient affected by atypical polypoid adenomyoma, mixed with well-differentiated endometrial-carcinoma is reported.	
<b>Perivascular epithelial cell tumor arising from polypoid adenomyoma: a case report</b>	104
T. Ishibashi, K. Nakayama, N. Nakayama, H. Katagiri, N. Ishikawa, K. Miyazaki - <i>Izumo, JAPAN</i> A rare case of uterine perivascular cell tumor originating from an endometrial adenomyoma is described.	

# Uterine malignant mixed Müllerian tumor after adjuvant tamoxifen treatment for breast cancer

C. Grigoriadis<sup>1</sup>, G. Androutopoulos<sup>2</sup>, D. Zygouris<sup>1</sup>, N. Arnogiannaki<sup>3</sup>, E. Terzakis<sup>1</sup>

<sup>1</sup>2nd Department of Gynecology, St. Savvas Anticancer-Oncologic Hospital, Athens

<sup>2</sup>Department of Obstetrics and Gynecology, University of Patras, Medical School, Rion

<sup>3</sup>Department of Pathology, St. Savvas Anticancer-Oncologic Hospital, Athens (Greece)

## Summary

**Background:** Uterine malignant mixed Müllerian tumor (MMMT), also known as carcinosarcoma, is a biphasic tumor of the female genital tract and demonstrates both malignant epithelial (carcinoma) and mesenchymal (sarcoma) components. The authors present two cases of uterine MMMT after adjuvant tamoxifen (TAM) treatment for breast cancer and a review of the current literature. **Cases:** The patients presented with a complaint of abnormal uterine bleeding. They both had a history of breast cancer Stage IIB previously treated with modified radical mastectomy, at 51 and 78 months, respectively. They also had history of tamoxifen treatment 20 mg daily for seven and 73 months respectively. They underwent total abdominal hysterectomy with bilateral salpingo-oophorectomy and total omentectomy. Histopathology revealed a uterine MMMT. Postoperatively, they received adjuvant chemotherapy and radiotherapy. One of the patients died 26 months after initial surgery due to uterine MMMT. **Conclusion:** Uterine MMMT is a rare, highly-aggressive, and rapidly-progressing tumor associated with a poor prognosis. Postmenopausal patients, with prolonged adjuvant TAM treatment for breast cancer, are at increased risk for the development of uterine MMMT.

**Key words:** Uterine malignant mixed Müllerian tumor; Uterine carcinosarcoma; Tamoxifen; Treatment; Prognosis.

## Introduction

Uterine malignant mixed Müllerian tumor (MMMT), also known as carcinosarcoma, is a biphasic tumor of the female genital tract and demonstrates both malignant epithelial (carcinoma) and mesenchymal (sarcoma) components [1, 2]. It is a very rare disease, accounting for 4.3% of all uterine malignant tumors [3]. Also, it has a worldwide annual incidence between 0.5 and 3.3 cases per 100.000 women [4, 5].

It usually occurs in postmenopausal women, although younger women may be affected. The median age at diagnosis of uterine MMMT is 62 years [6]. Uterine MMMT and endometrial cancer share a similar risk factor profile [7]. Risk factors for the development of uterine MMMT are: obesity, nulliparity, exposure to exogenous estrogens, and pelvic radiation [2-7].

The aim of this study was to describe the clinical characteristics, management, and prognosis of two patients with uterine MMMT after adjuvant tamoxifen (TAM) treatment for breast cancer that were diagnosed and treated in the Department and a review of the current literature.

## Case Reports

### Case 1

The patient, a 79-year-old gravida 2, para 2, postmenopausal Greek woman, presented with a complaint of abnormal uterine

bleeding. She had a history of breast cancer Stage IIB previously treated with modified radical mastectomy 51 months ago. Postoperatively, she received adjuvant chemotherapy and radiotherapy. She also received 20 mg TAM daily for seven months. Her family history revealed no evidence of cancer among the first-degree relatives.

A gynecologic examination did not reveal any abnormal findings. There were no palpable inguinal lymph nodes and the rest of pelvic examination was also normal.

Preoperative computer tomography (CT) of the abdomen and pelvis, and abdominal ultrasound (U/S) revealed irregular endometrial thickening. A CT of the chest, chest X-ray, intravenous pyelography (IVP), colonoscopy, and urethrocystoscopy were normal. Dilatation and curettage revealed uterine malignancy. Preoperative CA-125 was elevated at 120 U/ml.

During exploratory laparotomy, the patient underwent total abdominal hysterectomy with bilateral salpingo-oophorectomy and total omentectomy.

Histopathology revealed uterine MMMT. The epithelial component of uterine MMMT was adenocarcinoma and the mesenchymal component was leiomyosarcoma (Figures 1 and 2). The uterine tumor did not invade the myometrium. The ovaries and omentum were normal. The peritoneal washing smear was positive for malignant cells. The final diagnosis was Stage IA uterine MMMT according to FIGO staging system 2009 [8, 9].

The patient underwent postoperative adjuvant chemotherapy. She received six courses of carboplatin (400 mg/m<sup>2</sup>). She also received postoperatively 5,000 cGy of external and 2,000 cGy of intravaginal radiotherapy. However, 22 months after initial surgery for uterine MMMT, the patient presented with a complaint of abnormal vaginal bleeding. A gynecologic examination revealed local recurrence of the disease with in the vaginal vault with dimensions of 5 x 3.5 x 2 cm. A CT of the abdomen and pelvis, and histopathology, re-confirmed the clinical diagnosis.

Revised manuscript accepted for publication May 31, 2012

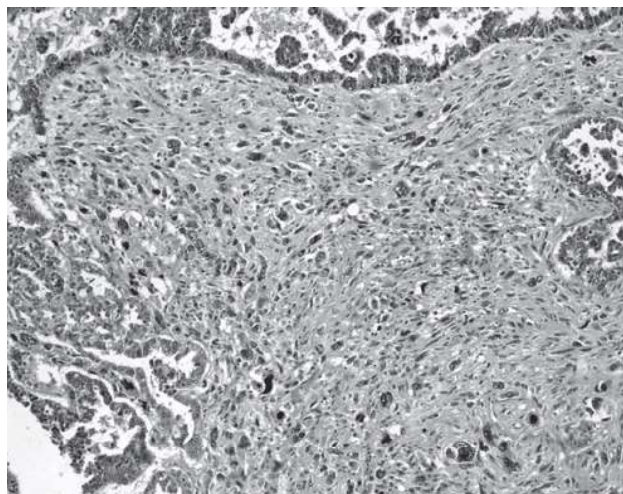


Fig. 1

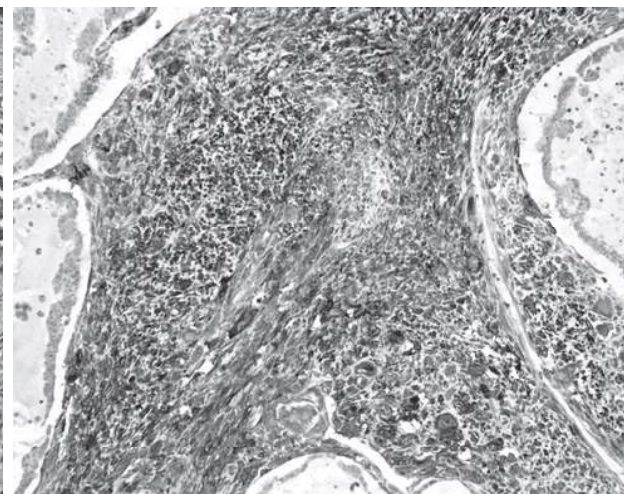


Fig. 2

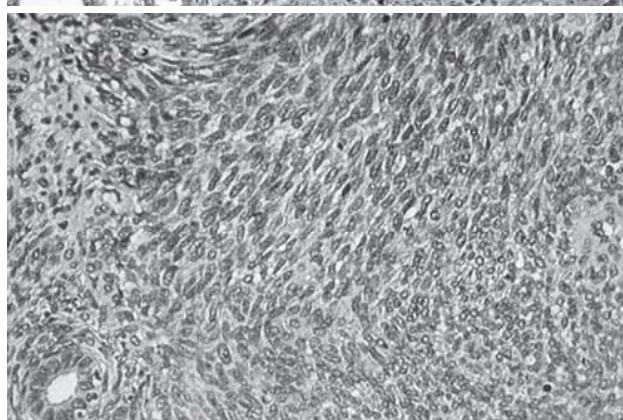


Fig. 3

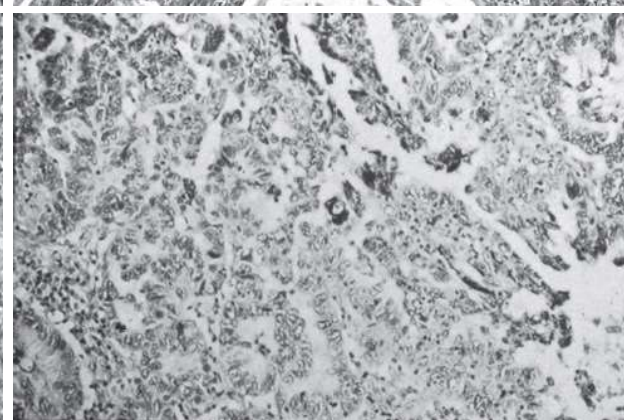


Fig. 4

Figure 1. — Case 1: Uterine malignant mixed Müllerian tumor (HE x 100).

Figure 2. — Case 1: Uterine malignant mixed Müllerian tumor (SMA x 100).

Figure 3. — Case 2: Uterine malignant mixed Müllerian tumor (HE x 100).

Figure 4. — Case 2: Uterine malignant mixed Müllerian tumor (HE x 100).

The patient underwent chemotherapy once again, but she received only three courses of carboplatin ( $400 \text{ mg/m}^2$ ) due to systemic complications. She died because of recurrent disease 26 months after initial surgery for uterine MMMT.

#### Case 2

The patient, a 81-year-old gravida 4, para 2, postmenopausal Greek woman, presented with a complaint of abnormal uterine bleeding. She had history of breast cancer Stage IIB previously treated with modified radical mastectomy 78 months ago. Postoperatively, she received adjuvant chemotherapy and radiotherapy. She also received 20 mg TAM daily for 73 months. Her family history revealed no evidence of cancer among the first-degree relatives.

A gynecologic examination did not reveal any abnormal findings. There were no palpable inguinal lymph nodes and the rest of pelvic examination was also normal.

Preoperative CT of the abdomen and pelvis, and abdominal U/S revealed irregular endometrial thickening. Preoperative CT of the chest, chest X-ray, IVP, colonoscopy, and urethroscopy were normal. Hysteroscopy and endometrial biopsy revealed uterine MMMT. Preoperative CA-125 was normal.

During exploratory laparotomy, the patient underwent total abdominal hysterectomy with bilateral salpingo-oophorectomy,

total omentectomy, pelvic and para-aortic lymph node dissection.

Histopathology revealed uterine MMMT. The epithelial component of uterine MMMT was adenocarcinoma and the mesenchymal component was endometrial stromal sarcoma (Figures 3 and 4). The uterine tumor did not invade the myometrium. The ovaries and omentum were normal. The peritoneal washing smear was positive for malignant cells. The final diagnosis was Stage IA uterine MMMT according to FIGO staging system 2009 [8, 9].

The patient underwent postoperative adjuvant chemotherapy. She received six courses of cisplatin ( $75 \text{ mg/m}^2$ ) and paclitaxel ( $175 \text{ mg/m}^2$ ). She also received postoperatively 5,000 cGy external and 2,000 cGy of intravaginal radiotherapy.

Follow-up at 24 months after initial surgery for uterine MMMT, with CT of the chest, abdomen, and pelvis, abdominal U/S, chest X-ray, IVP, colonoscopy, and urethroscopy, revealed no evidence of recurrence.

#### Discussion

Uterine MMMT is a biphasic tumor of the female genital tract composed of both malignant epithelial and mesenchymal components [1, 2]. The epithelial component of

uterine MMMT may be serous, endometrioid, clear cell, squamous or undifferentiated [2, 10-12]. The mesenchymal component of uterine MMMT may be homologous or heterologous. Homologous types contain only mesenchymal elements normally found in the uterus (endometrial stromal sarcoma, fibrosarcoma, leiomyosarcoma or undifferentiated sarcoma) [10-12]. Heterologous types contain some mesenchymal elements that are not usually found in the uterus (rhabdomyosarcoma, chondrosarcoma, osteosarcoma or liposarcoma) [10-12]. In the patients studied, the epithelial component of uterine MMMT was adenocarcinoma in both cases. Also, the mesenchymal component of uterine MMMT was leiomyosarcoma in one case and endometrial stromal sarcoma in the other case.

Although the precise histogenesis of uterine MMMT is still uncertain, there are four main theories regarding it: collision, combination, conversion, and composition [2, 10, 13-14]. Most uterine MMMT are monoclonal with the epithelial component being the driving force [2, 15]. However, a small subset of uterine MMMT is true collision tumors, consisting of independent unrelated carcinomas and sarcomas [2, 16]. It may be of prognostic significance to identify this subset of uterine MMMT [2].

TAM is a non-steroidal selective estrogen receptor modulator (SERM) that has potent anti-estrogenic activity in the breast, while displaying weak estrogen activity in the endometrium [17, 18]. A significant side-effect of TAM treatment, in postmenopausal women with breast cancer, and appears to have a proliferative effect on the endometrium [19]. This side-effect is correlated with the development of various endometrial pathologies, including hyperplasia, polyps, carcinoma, and sarcoma [17-19]. There is also increased risk for the development of uterine MMMT especially in postmenopausal patients with prolonged adjuvant TAM treatment [20-22]. Other risk factors for the development of uterine MMMT are: obesity, nulliparity, exposure to exogenous estrogens, and pelvic radiation [2, 7].

There may be an association between prolonged adjuvant TAM treatment (> five years) and the development of uterine MMMT [19]. As both epithelial and stromal cells in the uterus express estrogen receptors, it is possible that prolonged weak estrogen activity of TAM treatment in the endometrium may be associated with the development of uterine MMMT [20, 23]. Both patients presented were postmenopausal and received TAM treatment for seven and 73 months respectively.

Uterine MMMT most commonly occur as a solitary, large, soft, polypoid mass with hemorrhagic and necrotic regions [10, 12]. It usually fills and distends the endometrial cavity and invades the myometrium [10, 24].

The clinical presentation of uterine MMMT is usually nonspecific. The most common presenting signs and symptoms are: abnormal uterine bleeding, abdominal/pelvic pain, and abdominal/pelvic mass [10, 12, 24]. The patients presented with a complaint of abnormal uterine bleeding.

The nonspecific nature of signs and symptoms in

patients with uterine MMMT still renders preoperative diagnosis exceptional. Magnetic resonance imaging (MRI) findings are usually not pathognomonic and differential diagnosis includes endometrial cancer [25]. The final diagnosis of uterine MMMT is usually histological and sometimes is possible only after hysterectomy [12]. In many cases (> 50%), patients diagnosed at advanced stage disease [2, 12, 26-28]. In the patients presented, preoperative CT of the abdomen and pelvis, and U/S revealed irregular endometrial thickening.

Uterine MMMT primarily spread via lymphatics, similar to endometrial carcinomas [29]. Also, most patients with uterine MMMT die from local recurrence in the pelvis and abdomen rather than from metastatic disease [2, 30].

The most common sites of metastasis in uterine MMMT are: lung (49%), peritoneum (44%), pelvic and para-aortic lymph nodes (35%), adrenal gland, bones, heart, pericardium, and brain [2, 10, 12, 24].

However, recurrence rates after initial surgery and postoperative adjuvant therapy are between 47% - 64% [10, 28, 30]. Recurrence rate is 44% for homologous and 63% for heterologous uterine MMMT [30], and most of them are associated with distant metastases [10, 28].

Treatment of choice in patients with uterine MMMT is: total abdominal hysterectomy with bilateral salpingo-oophorectomy, total omentectomy, pelvic lymphadenectomy, para-aortic lymph node sampling, and maximal tumor debulking [10, 24]. However, the beneficial role of lymphadenectomy remains undetermined [31]. In node-negative patients, extended lymphadenectomy actually offers survival benefit [31, 32]. In node positive patients extended lymphadenectomy cannot improve survival due to the systematic spread of the disease [31, 32]. The patients presented underwent total abdominal hysterectomy with bilateral salpingo-oophorectomy and total omentectomy. Only one of them underwent pelvic and para-aortic lymph node dissection.

Uterine MMMT should be considered as metaplastic carcinoma and adjuvant treatment should be similar to that directed against aggressive subtypes of endometrial adenocarcinoma [2]. Also, high rates of postoperative local and distant relapse necessitate effective postoperative adjuvant chemotherapy and/or radiotherapy [6, 33, 34].

Adjuvant radiotherapy includes external pelvic radiotherapy and/or brachytherapy [24]. Data regarding the efficacy of adjuvant radiotherapy in patients with uterine MMMT are conflicting [24, 32, 35, 36]. It usually reduces the incidence of local recurrences; however, a beneficial effect on survival is inconsistent [35, 36]. The patients underwent postoperatively 5,000 cGy of external and 2,000 cGy of intravaginal radiotherapy.

Adjuvant chemotherapy should be similar to that directed against aggressive subtypes of endometrial adenocarcinoma [2, 6]. Combination chemotherapy with paclitaxel and carboplatin is effective in patients with uterine MMMT [37]. However, in advanced stage as well as in recurrent disease, adjuvant combination chemother-

apy with ifosfamide and paclitaxel should be considered [38]. The patients in this study underwent postoperative adjuvant chemotherapy.

Also, ErbB-targeted therapies might be a new therapeutic approach in patients with uterine MMMT and positive EGFR and erbB-2 receptors [24, 39-41].

Despite treatment modality, uterine MMMTs generally have poor prognosis. Advanced stage at initial diagnosis and intrinsic aggressiveness of uterine MMMTs, may explain dismal prognosis observed in those patients [2, 10]. Although very rare, they are associated to 16.4% of deaths caused by uterine malignancies [10, 12].

Prognostic factors for uterine MMMTs are: stage, age, histologic type of epithelial component, and presence of heterologous mesenchymal component [30, 42, 43]. However, the stage of the disease at initial diagnosis, is the most important prognostic factor [10, 42, 43].

The median survival in patients with uterine MMMT ranges between 16 and 40 months with death usually occurring within one to two years after initial diagnosis [10]. Also, five-year survival rates in patients with uterine MMMT are: 56% for Stage I, 31% for Stage II, 13% for Stage III, and 0% for Stage IV [28]. One of the patients in this study died 26 months after initial surgery due to uterine MMMT.

## Conclusion

Uterine MMMT is a rare, highly-aggressive, and rapidly-progressing tumor associated with a poor prognosis. Postmenopausal patients, with prolonged adjuvant TAM treatment for breast cancer, are at increased risk for the development of uterine MMMT. All these patients should be closely monitored, especially if they have abnormal uterine bleeding, abdominal/pelvic pain, and abdominal/pelvic mass.

## References

- [1] Silverberg S.G., Kurman R.J. (eds.): "Tumors of the uterine corpus and gestational trophoblastic disease". In: "Atlas of tumor pathology", Washington, Armed Forces Institute of Pathology, 1991, 166.
- [2] McCluggage W.G.: "Malignant biphasic uterine tumours: carcinosarcomas or metaplastic carcinomas?". *J. Clin. Pathol.*, 2002, 55, 321.
- [3] Young J.L., Jr., Percy C.L., Asire A.J., Berg J.W., Cusano M.M., Goeckler L.A. et al.: "Cancer incidence and mortality in the United States, 1973-77". *Natl. Cancer Inst. Monogr.*, 1981, 57, 1.
- [4] Harlow B.L., Weiss N.S., Lofton S.: "The epidemiology of sarcomas of the uterus". *J. Natl. Cancer Inst.*, 1986, 76, 399.
- [5] Brooks S.E., Zhan M., Cote T., Baquet C.R.: "Surveillance, epidemiology, and end results analysis of 2677 cases of uterine sarcoma 1989-1999". *Gynecol. Oncol.*, 2004, 93, 204.
- [6] Sutton G., Kauderer J., Carson L.F., Lentz S.S., Whitney C.W., Gallion H.: "Adjuvant ifosfamide and cisplatin in patients with completely resected stage I or II carcinosarcomas (mixed mesodermal tumors) of the uterus: a Gynecologic Oncology Group study". *Gynecol. Oncol.*, 2005, 96, 630.
- [7] Zelmanowicz A., Hildesheim A., Sherman M.E., Sturgeon S.R., Kurman R.J., Barrett R.J. et al.: "Evidence for a common etiology for endometrial carcinomas and malignant mixed mullerian tumors". *Gynecol. Oncol.*, 1998, 69, 253.
- [8] Pecorelli S.: "Revised FIGO staging for carcinoma of the vulva, cervix, and endometrium". *Int. J. Gynaecol. Obstet.*, 2009, 105, 103.
- [9] Prat J.: "FIGO staging for uterine sarcomas". *Int. J. Gynecol. Obstet.*, 2009, 104, 177.
- [10] Kanthan R., Senger J.L.: "Uterine carcinosarcomas (malignant mixed Müllerian tumours): a review with special emphasis on the controversies in management". *Obstet. Gynecol. Int.*, 2011, 2011, 470795.
- [11] Silverberg S.G., Major F.J., Blessing J.A., Fetter B., Askin F.B., Liao S.Y. et al.: "Carcinosarcoma (malignant mixed mesodermal tumor) of the uterus. A Gynecologic Oncology Group pathologic study of 203 cases". *Int. J. Gynecol. Pathol.*, 1990, 9, 1.
- [12] El-Nashar S.A., Mariani A.: "Uterine carcinosarcoma". *Clin. Obstet. Gynecol.*, 2011, 54, 292.
- [13] Gorai I., Yanagibashi T., Taki A., Udagawa K., Miyagi E., Nakazawa T. et al.: "Uterine carcinosarcoma is derived from a single stem cell: an in vitro study". *Int. J. Cancer*, 1997, 72, 821.
- [14] de Brito P.A., Silverberg S.G., Orenstein J.M.: "Carcinosarcoma (malignant mixed mullerian (mesodermal) tumor) of the female genital tract: immunohistochemical and ultrastructural analysis of 28 cases". *Hum. Pathol.*, 1993, 24, 132.
- [15] Thompson L., Chang B., Barsky S.H.: "Monoclonal origins of malignant mixed tumors (carcinosarcomas). Evidence for a divergent histogenesis". *Am. J. Surg. Pathol.*, 1996, 20, 277.
- [16] Wada H., Enomoto T., Fujita M., Yoshino K., Nakashima R., Kurachi H. et al.: "Molecular evidence that most but not all carcinosarcomas of the uterus are combination tumors". *Cancer Res.*, 1997, 57, 5379.
- [17] Ravazoula P., Androutsopoulos G., Zyli P., Michail G., Kardamakis D.M., Kourounis G.: "A clinicopathologic study on patients with endometrial cancer after adjuvant tamoxifen treatment for breast cancer: a single center experience". *Breast. J.*, 2006, 12, 578.
- [18] Androutsopoulos G., Adonakis G., Gkermepi M., Gkogkos P., Ravazoula P., Kourounis G.: "Expression of the epidermal growth factor system in endometrial cancer after adjuvant tamoxifen treatment for breast cancer". *Eur. J. Gynaecol. Oncol.*, 2006, 27, 490.
- [19] Cohen I.: "Endometrial pathologies associated with postmenopausal tamoxifen treatment". *Gynecol. Oncol.*, 2004, 94, 256.
- [20] McCluggage W.G., Abdulkader M., Price J.H., Kelehan P., Hamilton S., Beattie J. et al.: "Uterine carcinosarcomas in patients receiving tamoxifen. A report of 19 cases". *Int. J. Gynecol. Cancer*, 2000, 10, 280.
- [21] Bergman L., Beelen M., Gallee M., Hollema H., Benraadt J., van Leeuwen F.: "Risk and prognosis of endometrial cancer after tamoxifen for breast cancer. Comprehensive Cancer Centres ALERT Group. Assessment of Liver and Endometrial cancer Risk following Tamoxifen". *Lancet*, 2000, 356, 881.
- [22] Curtis R.E., Freedman D.M., Sherman M.E., Fraumeni J.F. Jr.: "Risk of malignant mixed mullerian tumors after tamoxifen therapy for breast cancer". *J. Natl. Cancer Inst.*, 2004, 96, 70.
- [23] Treilleux T., Mignotte H., Clement-Chassagne C., Guastalla P., Bailly C.: "Tamoxifen and malignant epithelial-non-epithelial tumours of the endometrium: report of six cases and review of the literature". *Eur. J. Surg. Oncol.*, 1999, 25, 477.
- [24] Villena-Heinsen C., Dising D., Fischer D., Griesinger G., Maas N., Diedrich K. et al.: "Carcinosarcomas - a retrospective analysis of 21 patients". *Anticancer Res.*, 2006, 26, 4817.
- [25] Bharwani N., Newland A., Tunariu N., Babar S., Sahdev A., Rockall A.G. et al.: "MRI appearances of uterine malignant mixed mullerian tumors". *A.J.R. Am. J. Roentgenol.*, 2010, 195, 1268.
- [26] Kernochan L.E., Garcia R.L.: "Carcinosarcomas (malignant mixed Mullerian tumor) of the uterus: advances in elucidation of biologic and clinical characteristics". *J. Natl. Compr. Canc. Netw.*, 2009, 7, 550.
- [27] Vaidya A., Horowitz N., Oliva E., Halpern E., Duska L.: "Uterine malignant mixed mullerian tumors should not be included in studies of endometrial carcinoma". *Gynecol. Oncol.*, 2006, 103, 684.
- [28] Sartori E., Bazzurini L., Gadducci A., Landoni F., Lissoni A., Maggino T. et al.: "Carcinosarcoma of the uterus: a clinicopathological multicenter CTF study". *Gynecol. Oncol.*, 1997, 67, 70.
- [29] Sreenan J., Hart W.: "Carcinosarcomas of the female genital tract. A pathologic study of 29 metastatic tumors: further evidence for the dominant role of the epithelial component and the conversion theory of histogenesis". *Am. J. Surg. Pathol.*, 1995, 19, 666.
- [30] Major F.J., Blessing J.A., Silverberg S.G., Morrow C.P., Creasman W.T., Currie J.L. et al.: "Prognostic factors in early-stage uterine sarcoma. A Gynecologic Oncology Group study". *Cancer*, 1993, 71, 1702.

- [31] Vorgias G., Fotiou S.: "The role of lymphadenectomy in uterine carcinosarcomas (malignant mixed mullerian tumours): a critical literature review". *Arch. Gynecol. Obstet.*, 2010, 282, 659.
- [32] Nemani D., Mitra N., Guo M., Lin L.: "Assessing the effects of lymphadenectomy and radiation therapy in patients with uterine carcinosarcoma: a SEER analysis". *Gynecol. Oncol.*, 2008, 111, 82.
- [33] Galaal K., Kew F.M., Tam K.F., Lopes A., Meirovitz M., Naik R. *et al.*: "Evaluation of prognostic factors and treatment outcomes in uterine carcinosarcoma". *Eur. J. Obstet. Gynecol. Reprod. Biol.*, 2009, 143, 88.
- [34] Gonzalez Bosquet J., Terstriep S.A., Cliby W.A., Brown-Jones M., Kaur J.S., Podratz K.C. *et al.*: "The impact of multi-modal therapy on survival for uterine carcinosarcomas". *Gynecol. Oncol.*, 2010, 116, 419.
- [35] Knocke T.H., Weitmann H.D., Kucera H., Kolbl H., Pokrajac B., Potter R.: "Results of primary and adjuvant radiotherapy in the treatment of mixed Mullerian tumors of the corpus uteri". *Gynecol. Oncol.*, 1999, 73, 389.
- [36] Clayton Smith D., Kenneth Macdonald O., Gaffney D.K.: "The impact of adjuvant radiation therapy on survival in women with uterine carcinosarcoma". *Radiother. Oncol.*, 2008, 88, 227.
- [37] Hoskins P.J., Le N., Ellard S., Lee U., Martin L.A., Swenerton K.D. *et al.*: "Carboplatin plus paclitaxel for advanced or recurrent uterine malignant mixed mullerian tumors. The British Columbia Cancer Agency experience". *Gynecol. Oncol.*, 2008, 108, 58.
- [38] Galaal K., Godfrey K., Naik R., Kucukmetin A., Bryant A.: "Adjuvant radiotherapy and/or chemotherapy after surgery for uterine carcinosarcoma". *Cochrane Database Syst. Rev.*, 2011, 1, CD006812.
- [39] Livasy C.A., Reading F.C., Moore D.T., Boggess J.F., Lininger R.A.: "EGFR expression and HER2/neu overexpression/amplification in endometrial carcinosarcoma". *Gynecol. Oncol.*, 2006, 100, 101.
- [40] Sawada M., Tsuda H., Kimura M., Okamoto S., Kita T., Kasamatsu T. *et al.*: "Different expression patterns of KIT, EGFR, and HER-2 (c-erbB-2) oncoproteins between epithelial and mesenchymal components in uterine carcinosarcoma". *Cancer Sci.*, 2003, 94, 986.
- [41] Adonakis G., Androutsopoulos G.: "The role of ErbB receptors in endometrial cancer". In: "Cancer of the uterine endometrium - advances and controversies". Saldivar J.S. ed., Rijeka. InTech, 2012, 23.
- [42] Iwasa Y., Haga H., Konishi I., Kobashi Y., Higuchi K., Katsuyama E. *et al.*: "Prognostic factors in uterine carcinosarcoma: a clinicopathologic study of 25 patients". *Cancer*, 1998, 82, 512.
- [43] Nordal R.R., Kristensen G.B., Stenwig A.E., Nesland J.M., Pettersen E.O., Trope C.G.: "An evaluation of prognostic factors in uterine carcinosarcoma". *Gynecol. Oncol.*, 1997, 67, 316.

Address reprint requests to:  
 G. ANDROUTSOPOULOS, M.D.  
 Nikolaou Apostoli 21  
 Patras 26332 (Greece)  
 e-mail: androutsopoulosgeorgios@hotmail.com