

# europaean journal of gynaecological oncology

an International Journal

*Founding Editor*

**A. Onnis**

*Montréal (Canada)*

*Editors-in-Chief*

**M. Marchetti**

*Montréal (Canada)*

**P. Bószé**

*Budapest (Hungary)*

*Associate Editor*

**T. Maggino**

*Padua (Italy)*

*Assistant Editor*

**J. Wilson**

*San Diego - CA (USA)*

*Editorial Board*

- |   |  |  |
|---|--|--|
| Allen H.H., <i>London, Ontario (Canada)</i>       | Geisler H.E., <i>Indianapolis, IN (USA)</i>                | Monsonogo J., <i>Paris (France)</i>        |
| Ayhan A., <i>Ankara (Turkey)</i>                  | Gorins A., <i>Paris (France)</i>                           | Pálfalvi L., <i>Budapest, (Hungary)</i>    |
| Balat O., <i>Graziantep (Turkey)</i>              | Heintz A.P.M.,<br><i>Utrecht (The Netherlands)</i>         | Piura B., <i>Beer Sheva (Israel)</i>       |
| Balega J., <i>Birmingham, England (UK)</i>        | Ioannidou-Mouzaka L.,<br><i>Athens (Greece)</i>            | Piver S.M., <i>Buffalo, NY (USA)</i>       |
| Bănceanu G., <i>Bucarest (Romania)</i>            | Jordan J.A.,<br><i>Birmingham, England (UK)</i>            | Rakar S., <i>Ljubljana (Slovenia)</i>      |
| Basta A., <i>Krakow (Poland)</i>                  | Klastersky J., <i>Bruxelles (Belgium)</i>                  | Shepherd J.H., <i>London, England (UK)</i> |
| Bender H.C., <i>Dusseldorf (Germany)</i>          | Kubista E., <i>Vienna (Austria)</i>                        | Siklòs P., <i>Budapest (Hungary)</i>       |
| Charkviani T., <i>Tbilisi (Georgia)</i>           | Lee Y.S., <i>Daegu (South Korea)</i>                       | Smit B.J., <i>Tygerberg (South Africa)</i> |
| Chiarelli S., <i>Padua (Italy)</i>                | Markowska J., <i>Poznan (Poland)</i>                       | Stelmachów J., <i>Warsaw (Poland)</i>      |
| De Oliveira C.F., <i>Coimbra (Portugal)</i>       | Mariani A., <i>Rochester, MN (USA)</i>                     | Syrjänen K., <i>Turku (Finland)</i>        |
| Dexeus S. Jr., <i>Barcelona (Spain)</i>           | Marth C., <i>Innsbruck (Austria)</i>                       | Tjalma W., <i>Antwerpen (Belgium)</i>      |
| Di Paola G.R.,<br><i>Buenos Aires (Argentina)</i> | Massuger Leon F.A.G.,<br><i>Nijmegen (The Netherlands)</i> | Ungár L., <i>Budapest (Hungary)</i>        |
| Di Re F., <i>Milan (Italy)</i>                    | Menczer J., <i>Savyon (Israel)</i>                         | Vermorken J.B., <i>Edegem (Belgium)</i>    |
| Di Saia P., <i>Orange, CA (USA)</i>               |  | Wang P.H., <i>Taipei (Taiwan)</i>          |
| Elit L., <i>Hamilton (Canada)</i>                 |  | Winter R., <i>Graz (Austria)</i>           |
| Friedrich M., <i>Krefeld (Germany)</i>            |  | Yokoyama Y., <i>Hirosaki (Japan)</i>       |

*Publishing Organization (M. Morsani):*

I.R.O.G. CANADA, Inc. - 4900 Côte St-Luc - Apt # 212 - Montréal, Qué. H3W 2H3 (Canada)  
Tel. +514-4893242 - Fax +514-4854513 - E-mail: canlux@mgroup-online.com - www.irog.net

*Editorial Office (M. Critelli):*

Galleria Storione, 2/A - 35123 Padua (Italy) - Tel. (39) 049 8756900 - Fax (39) 049 8752018  
E-mail: irog@onnisanantonio.191.it

EUROPEAN JOURNAL OF GYNAECOLOGICAL ONCOLOGY (ISSN 0392-2936) publishes original peer reviewed works in the fields of female genital cancers and related subjects and also proceedings of gynecologic oncology society meetings all over the world. The Journal is covered by **CURRENT CONTENTS, SCISEARCH, RESEARCH ALERT, INDEX MEDICUS, MEDLINE, EMBASE/Excerpta Medica, CURRENT ADVANCES IN CANCER RESEARCH, BIOSIS.**

<b>Long-term disease-free survival in three ovarian cancer patients with a single relapse</b>	321
C.Y. Chen, H.P. Chang, K.K. Ng, C.C. Wang, C.H. Lai, A. Chao - <i>Taoyuan, TAIWAN</i>	
The cases of three patients affected by first relapse of ovarian cancer and with long-term disease-free survival are presented.	
<b>Endometrioid ovarian cancer arising from an endometriotic cyst in a young patient</b>	324
D. Zygouris, V. Leontara, G.M. Makris, C. Chrelias, E. Trakakis, Ch. Christodoulaki, P. Panagopoulos - <i>Athens, GREECE</i>	
Endometriosis-associated ovarian cancer.	
<b>Removal of a vaginal leiomyoma presenting as tumor previum allowing vaginal birth</b>	326
V. Boškovic, S. Vrzic-Petronijevic, M. Petronijevic, J. Atanackovic, D. Bratic - <i>Belgrade, SERBIA</i>	
Case report about removal of vaginal leiomyoma presented as tumor previum was described. Removal of the tumor allowed vaginal birth.	
<b>Endometrial stromal sarcoma in a 29-year-old patient. Case report and review of the literature</b>	328
C. Sofoudis, T. Kalampokas, C. Grigoriadis, E. Kalampokas, K. Bakalianou, N. Salakos - <i>Athens, GREECE</i>	
A case of endometrial stromal sarcoma in a young patient together with a literature review.	
<b>Primary ovarian leiomyosarcoma</b>	331
D. Zygouris, G. Androutsopoulos, C. Grigoriadis, N. Arnogiannaki, E. Terzakis - <i>Athens, GREECE</i>	
Primary ovarian leiomyosarcoma: a case report and review of the literature.	
<b>Primary retroperitoneal mucinous cystadenoma adjacent to the kidney: report of two cases and review</b>	334
S. Cheng, Y. Chen, L. Xu, Z. Zhang, G.Q. Ding - <i>Hangzhou, CHINA</i>	
Two cases of retroperitoneal cystadenoma adjacent to the kidney are reported.	

#### ERRATA - CORRIGE

##### **Tumor of the mesosalpinx: case report of a female adnexal tumor of probable Wolffian origin**

Vol. XXXIII, n. 2, 2012, page 233

##### **Errata:**

X. Tianmin<sup>1</sup>, C. Weiqim<sup>1</sup>, C. Mianhua<sup>1</sup>, L. Xiaocui<sup>1</sup>, G. Hongwen<sup>2</sup>, Y. Min<sup>2</sup>

##### **Corrige:**

Xu Tianmin<sup>1</sup>, Chang Weiqin<sup>1</sup>, Cui Manhua<sup>1</sup>, Li Xiaocui<sup>1</sup>, Gao Hongwen<sup>2</sup>, Yao Min<sup>2</sup>

EUROPEAN JOURNAL OF GYNAECOLOGICAL ONCOLOGY

Vol. XXXIII, Number 3, 2012

ISSN: 0392-2936

I.R.O.G. CANADA, Inc.

Publisher's office: 4900 Côte St. Luc - Apt. 212 - Montréal, Québec H3W 2H3 (Canada) - Tél.: (514) 4893640-4893242 - Fax: (514) 4854513

E-mail: canlux@mgrounline.com - www.irog.net

ALL RIGHTS RESERVED

No part of this publication may be reproduced or transmitted in any form or by any means, electronic or mechanical, including photocopies, recordings, nor any information storage and retrieval system without written permission from the copyright owner.

Printed in Italy

# Endometrioid ovarian cancer arising from an endometriotic cyst in a young patient

D. Zygouris<sup>1</sup>, V. Leontara<sup>2</sup>, G.M. Makris<sup>1</sup>, C. Chrelias<sup>1</sup>, E. Trakakis<sup>1</sup>,  
Ch. Christodoulaki, P. Panagopoulos<sup>1</sup>

<sup>1</sup>3rd Department of Obstetrics & Gynaecology University of Athens; <sup>2</sup>Department of Pathology University of Athens (Greece)

## Summary

**Objective:** To present a case of a young woman with ovarian endometrioid adenocarcinoma arising from an endometriotic cyst and review of the literature. **Case Report:** A 33-year-old woman, gravid 2, para 2 was admitted to our department with a 5 cm adnexal mass. Diagnostic laparoscopy was performed and pathological examination demonstrated an endometriotic cyst with an area of an ovarian endometrioid adenocarcinoma well differentiated, with no capsular invasion. One month after the operation the patient underwent MRI which revealed a 6 cm mass in the Douglas pouch. The multidisciplinary oncology council decided on exploratory laparotomy, which revealed no pathology. After that the multidisciplinary oncology council decided on adjuvant chemotherapy and the patient received four cycles of carboplatin/taxol. **Conclusion:** It should always be considered that even when there are no risk factors for malignancy occurrence, a high index of suspicion is necessary and will help to prevent delay in the diagnosis of this rare neoplasm.

**Key words:** Endometriosis; Endometriosis-associated cancer; Ovarian endometrioid adenocarcinoma.

## Introduction

Endometriosis is the presence of endometrial glands and stroma outside the uterus. It is a common problem among women in reproductive age having an incidence up to 10% in the general female population [1, 2]. Endometriosis is an estrogen-dependent disease and is a usual cause of pelvic pain and infertility.

Endometriosis is very common in the ovaries, fallopian tubes, uterosacral ligaments and lateral pelvic peritoneum. Less commonly it can be found in the vagina, rectovaginal septum and the colon and rectum.

Many studies correlate endometriosis with clear cell and endometrioid cancer in premenopausal women with large endometriomas. We present a case of a 33-year-old woman with a 5 cm endometrioma who had ovarian endometrioid adenocarcinoma together with a review of the literature.

## Case Report

A 33-year-old-woman, gravid 2, para 2 was admitted to our department with a 5 cm adnexal mass. The patient had had chronic pelvic pain for the previous two years, but she did not complain about dysmenorrhea or dyspareunia. Her physical examination revealed a soft mass in the area of the left adnexa and no pain during palpation of the uterosacral ligaments. An abdominal ultrasonography showed a 5 x 3 cm endometrioma of the left ovary. The serum concentration of CA 125 was within normal limits (19.8 IU/ml, normal range < 35 IU/ml).

After written and informed consent of the patient was obtained, a diagnostic laparoscopy was performed. Intraoperative observation demonstrated an endometrioma of the left ovary with a maximum diameter of about 5 cm; the rest of the

abdominal organs were normal. Peritoneal washing was obtained and the mass was removed intact and sent for frozen section examination which suggested no existence of malignancy. Pathological examination demonstrated an endometriotic cyst with an area of well differentiated ovarian endometrioid adenocarcinoma and no capsular invasion. It consisted of confluent glands and cribriform areas. The neoplastic cells included rounded nuclei, clumped chromatin and small nucleoli. Mitotic figures were scanty. One month after the operation the patient underwent magnetic resonance imaging (MRI), which revealed a 6 cm mass in the Douglas pouch. The multidisciplinary oncology council decided on exploratory laparotomy which revealed no pathology. Nevertheless, total hysterectomy with bilateral oophorectomy, omentectomy, appendectomy and pelvic lymphadenectomy were performed. Recovery was uneventful and pathology examination revealed no cancer cells. After that the multidisciplinary oncology council decided on adjuvant chemotherapy and the patient received four cycles of carboplatin/taxol.

## Discussion

Criteria to identify malignant tumors arising from endometriosis were first proposed by Sampson in 1927 [3] and in 1953 Scott [4] added stricter criteria. The frequency of malignant transformation of endometriosis is not exactly evaluated, but it is estimated that 1% or less of women will develop neoplasms associated with endometriosis [5].

The ovary is by far the most common site where malignancy arises in association with endometriosis, accounting for about 75% of such cases [6]. Endometrioid adenocarcinoma and clear cell adenocarcinoma are the most common malignancies found to arise in ovarian endometriosis, accounting for roughly two-thirds of all such reported cases [7]. While endometrioid adenocarcinoma is the more common of the two entities by a ratio between 1.3:1 and about 4:1, women who have clear cell

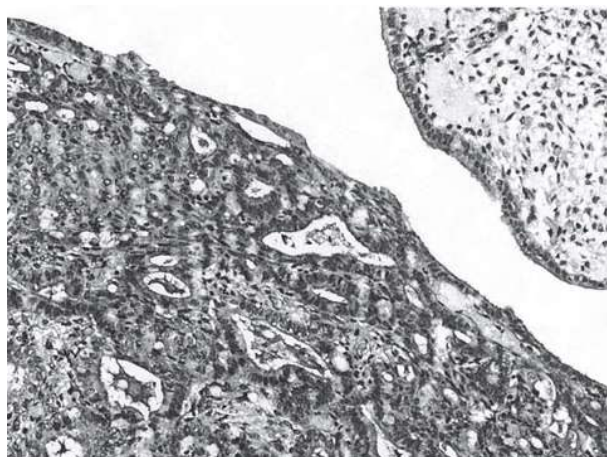


Figure 1. — Well differentiated endometrioid adenocarcinoma arising in an ovarian endometriotic cyst (H-E x 200).

adenocarcinoma are often reported to have a much higher frequency of coexistent pelvic endometriosis.

Recent data suggest that patients with long-standing endometriosis have a higher risk of developing ovarian cancer [8]. In our case, the patient reported chronic pelvic pain of two years duration and no other sign of endometriosis such as dyspareunia or dysmenorrhea. Moreover, endometriosis did not result in infertility, as she had had two normal conceptions and labors. Previous publications considered infertility an established risk factor for ovarian cancer [9], explaining the correlation between ovarian endometriosis and malignancy.

Kobayashi *et al.* found that excess risk for ovarian cancer increases markedly with increasing age at diagnosis of ovarian endometriomas [10]. The risk of ovarian cancer was restricted to women after the age of 40. We report the case of a young patient, 33 years old, with an endometrioma measuring 5 cm. In a Japanese study tumor size > 9 cm was found as an independent predictive factor for development of ovarian cancer [10].

Serum level of CA 125 is a marker of ovarian cancer, but it also increases in cases of endometriosis. Elevated serum CA 125 is expected in patients with endometrioid epithelial ovarian cancer and concurrent endometriosis. In our case the preoperative CA 125 was within normal limits, so no malignancy occurrence was suspected.

Today we treat almost all cases of endometriomas by laparoscopy. Preoperative transvaginal sonography has

changed the approach to diagnosis of cystic endometriosis. Our case report shows that even when there are no risk factors for malignancy occurrence, a high index of suspicion is necessary and will help to prevent delay in diagnosis of this rare neoplasm. Furthermore, the surgeon must be very careful to avoid intraoperative rupture of the ovarian cyst.

Recent papers show a role of K-ras and PTEN in the development of endometriosis and ovarian cancer in a mouse model [11]. It seems though that there is a long way to go, in order to completely understand the pathophysiology and the biologic mechanisms involved in the malignant transformation process.

## References

- [1] Giudice L.C., Kao L.C.: "Endometriosis". *Lancet*, 2004, 364, 1789.
- [2] Cramer D.W., Missmer S.A.: "The epidemiology of endometriosis". *Ann. N.Y. Acad. Sci.*, 2002, 955, 11.
- [3] Sampson J.A.: "Metastatic or embolic endometriosis, due to the menstrual dissemination of endometrial tissue into the venous circulation". *Am. J. Pathol.*, 1927, 3, 93.
- [4] Scott R.B.: "Malignant changes in endometriosis". *Obstet. Gynecol.*, 1953, 2, 283.
- [5] Heaps J.M., Nieberg R.K., Berek J.S.: "Malignant neoplasms arising in endometriosis". *Obstet. Gynecol.*, 1990, 75, 1023.
- [6] Ness R.B.: "Endometriosis and ovarian cancer: thoughts on shared pathophysiology". *Am. J. Obstet. Gynecol.*, 2003, 189, 280.
- [7] Stern R.C., Dash R., Bentley R.C., Snyder M.J., Haney A.F., Robboy S.J.: "Malignancy in endometriosis: frequency and comparison of ovarian and extraovarian types". *Int. J. Gynecol. Pathol.*, 2001, 20, 133.
- [8] Melin A., Sparén P., Persson I., Bergqvist A.: "Endometriosis and the risk of cancer with special emphasis on ovarian cancer". *Hum. Reprod.*, 2006, 21, 1237.
- [9] Weiss N.S.: "Measuring the separate effects of low parity and its antecedents on the incidence of ovarian cancer". *Am. J. Epidemiol.*, 1988, 128, 451.
- [10] Kobayashi H., Sumimoto K., Moniwa N., Imai M., Takakura K., Kuromaki T. *et al.*: "Risk of developing ovarian cancer among women with ovarian endometrioma: a cohort study in Shizuoka, Japan". *Int. J. Gynecol. Cancer*, 2007, 17, 37.
- [11] Dinulescu D.M., Ince T.A., Quade B.J., Shafer S.A., Crowley D., Jacks T.: "Role of K-ras and Pten in the development of mouse models of endometriosis and endometrioid ovarian cancer". *Nat. Med.*, 2005, 11, 63.

Address reprint requests to:  
P. PANAGOPOULOS, M.D.  
Tainarou 76  
16561 Athens (Greece)  
e-mail: paninosrafaela@yahoo.gr